

Macroanatomical morphology of superior temporal lobe in adults with dyslexia

Alexandra M. Kapadia^{1*}, Gabrielle-Ann Torre¹, Terri L. Scott², Yaminah D. Carter¹, Tyler K. Perrachione¹



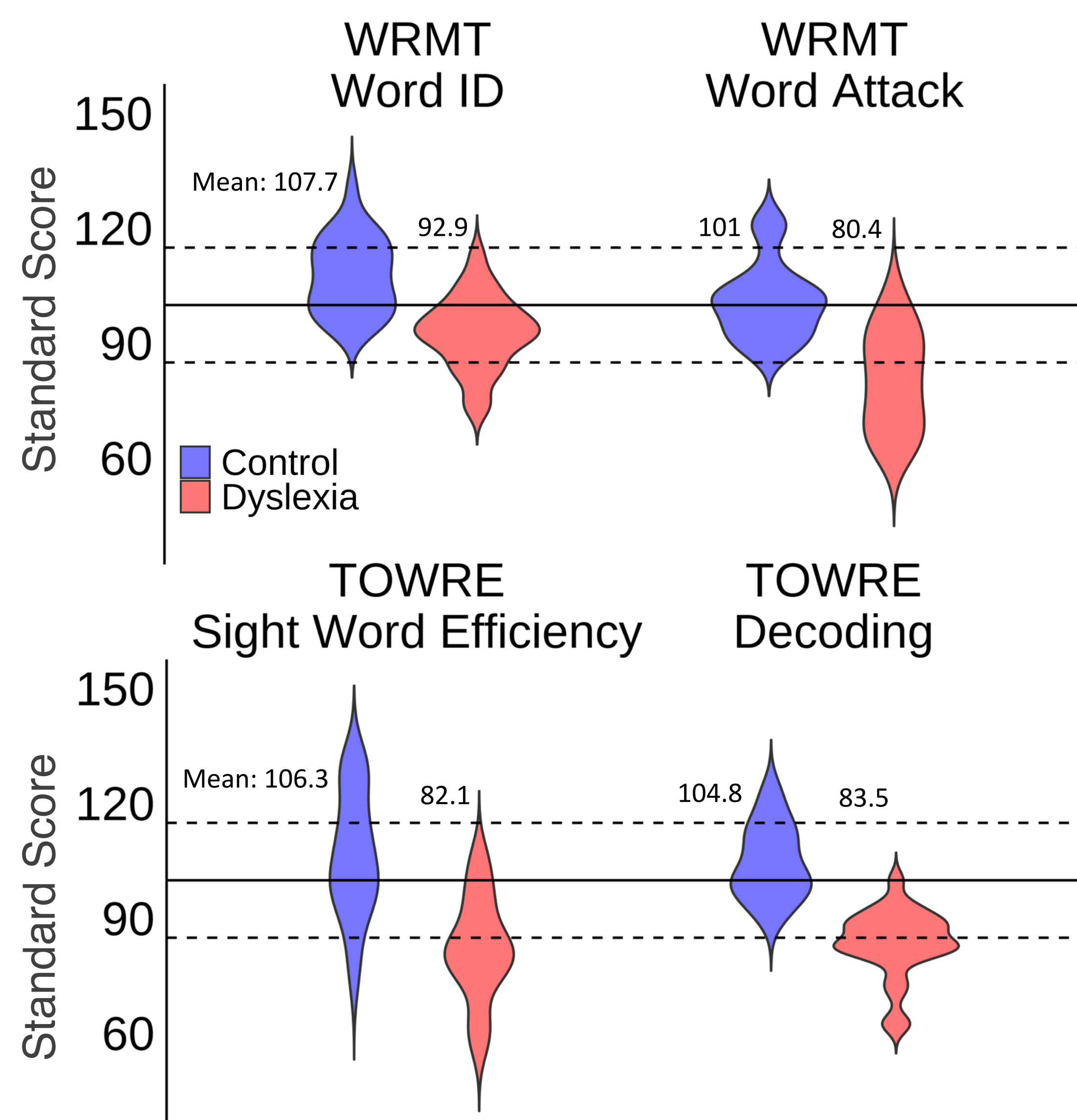
¹Department of Speech, Language & Hearing Sciences, ²Graduate Program for Neuroscience, Boston University; *Correspondence: akapadia@bu.edu
A PDF of this poster can be found at <http://sites.bu.edu/cnrlab/publications/conference-presentations-abstracts/>

Introduction

- The superior temporal lobe contains key regions for processing speech and language, among which the transverse temporal gyrus (Heschl's gyrus – HG) is known to contain primary auditory cortex.
- However, the morphology of HG is highly variable across individuals.
- Three broad patterns have been identified: a single gyrus, a partial duplication encompassing two gyri with a shared stem, and a complete duplication with individual stems (*examples at right*).
- Previous smaller-N studies have found that more complex morphological patterns may occur more frequently in individuals with developmental reading or language disorders.
- Research question:** In larger samples is this variability enhanced in groups with developmental disorders and what are other useful metrics for characterizing these variations?

Participants and data acquisition

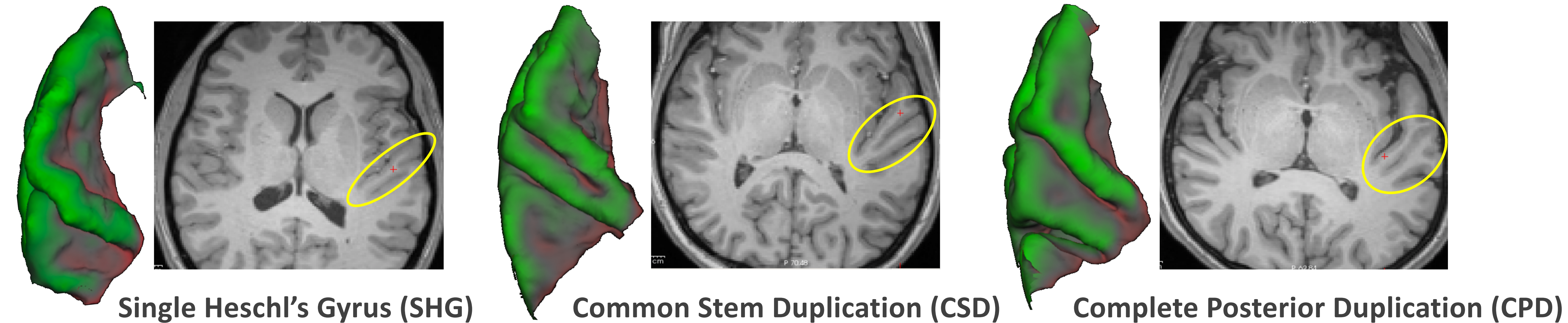
- Participants:** 48 native speakers of American English: 24 adults with dyslexia (20 female; age 18 – 28, mean = 22.5 years) & 24 adults with typical reading skills (13 female; age 19 – 32, mean = 23.1 years).
- No significant difference in nonverbal IQ** (measured by the KBIT) : Control group mean = 114.2, Dyslexia group mean = 109.5



- Structural images:** whole-head, high resolution T1- and T2-weighted anatomical volumes were acquired on a Siemens Trio 3T scanner with a 32-channel phased array head coil.

Classification of gyral morphology

- Morphological classification on the pial surface was confirmed in the volume.
- Counts for each pattern were sorted by hemisphere and by group.

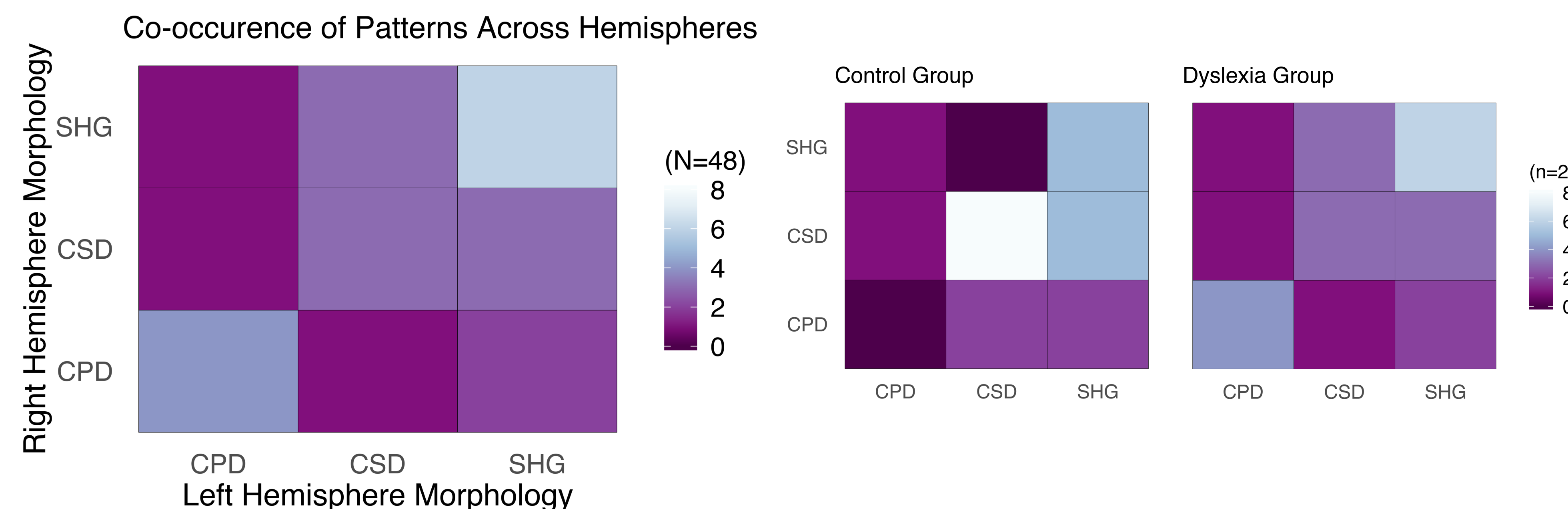


LEFT HEMISPHERE				RIGHT HEMISPHERE			
Group	SHG	CSD	CPD	Group	SHG	CSD	CPD
Control	12	10	2	Control	6	14	4
Dyslexia	11	7	6	Dyslexia	10	7	7

- No significant group differences across patterns in the left hemisphere ($\chi^2 = 1.75, p = 0.417$).
- No significant group differences across patterns in the right hemisphere ($\chi^2 = 0.75, p = 0.687$).

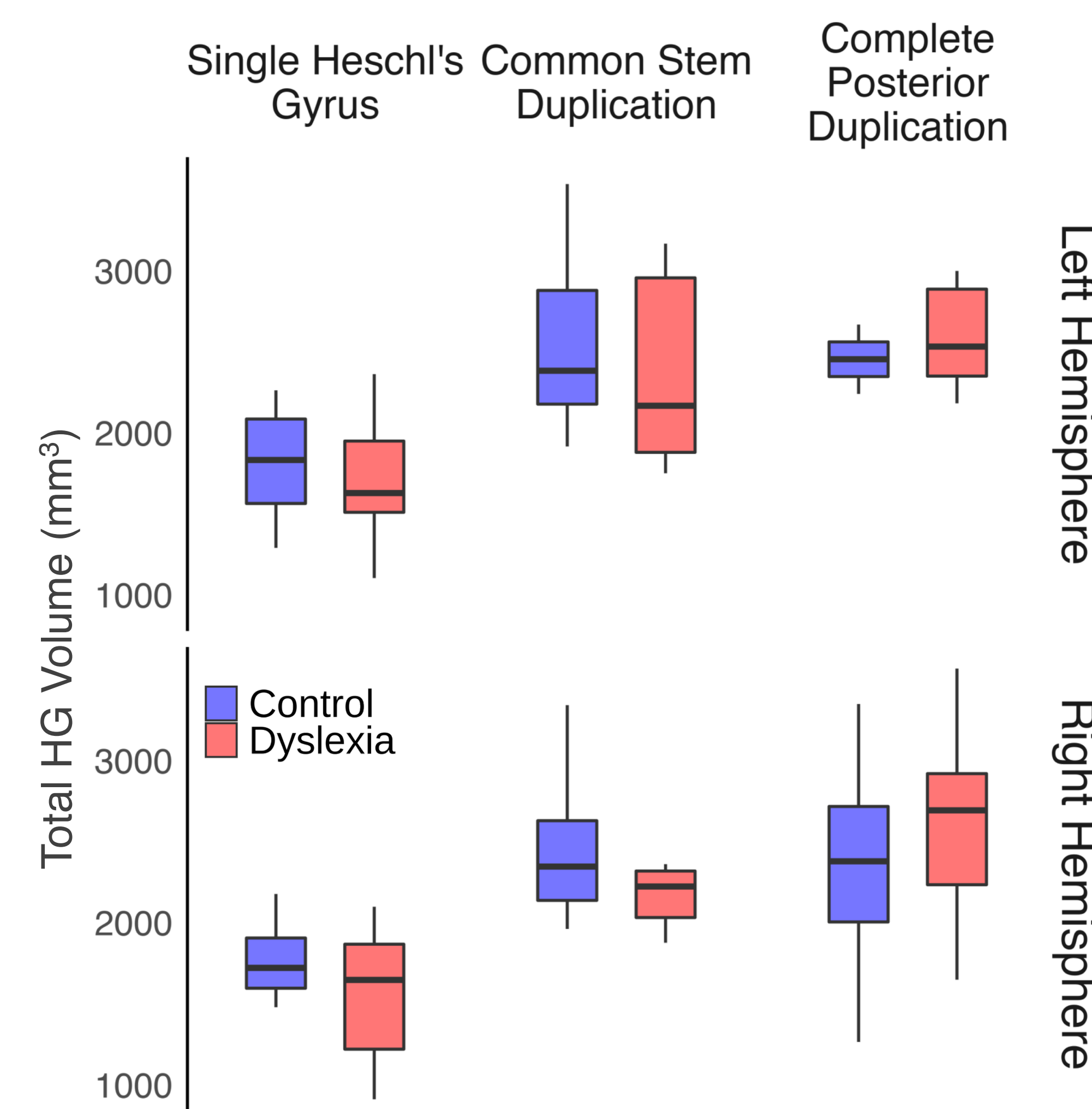
No significant differences were found across experimental groups for number of counts, or frequency of occurrence in the sample, of each morphological pattern.

The matrices to the left show that a single gyrus in each hemisphere is the most commonly occurring pattern; but the same morphological type co-occurring in each hemisphere for the same subject accounts for a minority of observations.



Volume analysis

- Preliminary volume analyses investigate the total volume across patterns.
- Total volume increases with morphological complexity.
- No significant differences were found across experimental groups for total volume in each morphological pattern.
- Future volume measurements will aim to measure the independent volume contributions of the different portions of HG (the stem, and the first and second gyri) and posterior areas (planum temporale).



Discussion

- No group differences in frequency of occurrence of morphological patterns was found.
- Preliminary volume analyses also reveal no group differences.
- This work is part of an ongoing effort in a sample of N>1000 of children and adults with and without dyslexia.
- Future analysis will focus on characterizing dyslexia across the age span in the context of a suite of neuroanatomical features, including further investigation into the microanatomical morphology of Heschl's gyrus.

References: [1] Leonard, C.M., et al. (1998). Normal variation in the frequency and location of human auditory cortex landmarks Heschl's gyrus: where is it?. *Cereb. Cortex.* 8(5), 397-406. [2] Altarelli, I., et al. (2014). Planum temporale asymmetry in developmental dyslexia: revisiting an old question. *Human Brain Mapping.* 35(12), 5717-5735. [3] Da Costa, S., et al. (2011). Human primary auditory cortex follows the shape of Heschl's gyrus. *J. Neurosci.* 31(40).

Funding: This work was supported by the National Institutes of Health under award numbers R03 DC014045 and R03 HD096098 to TP. AK was supported under NIH training grant T32 DC013017.