

ERG Testing in Clinical Practice

ERG Case Review: Epiretinal Membrane

Case ID: 11EM

Patient Work-Up	
Gender	Female
Age	60
Ethnicity	White
Complaints/Symptoms	Floaters, occasional visual disturbances
Personal History	Hypertension
Family History	None
Height / Weight	5f / 175Lb
BP	174/91
Pulse	68
IOP (mmHg) OD	15
IOP (mmHg) OS	16
Refraction OD	+2.00 -1.00 x 155 +2.75
Refraction OS	+2.25 -2.00 x 180 +2.75
VCVA OD	20/25
VCVA OS	20/30
Preliminary Diagnosis	Hypertension, Cataract, Epiretinal Membrane (ERM)

Tests Performed

- **Visual Field:** shows a normal response OU with good reliability.
- **OCT Macular Protocol:** reveals an increase of the internal limiting membrane in the foveal area and also some folds in OD parafoveal area.
- **ERG Concentric Stimulus Field Protocol:** shows abnormal waveform shapes for both OD and OS with Magnitude values within acceptable statistical ranges.
- **Slit Lamp Biomicroscopy:** (as described by the physician) reveals nuclear sclerosis, folds and rupture of Bowman's membrane and cellophane appearance in the macular area corresponding to the diagnosis of ERM on both eyes.

Conclusion

Patient complained of occasional visual disturbances. OCT findings are consistent with the diagnosis of ERM. Although the waveform shape of the pattern ERG does not show three equally spaced sinusoidal-like peaks, the quantitative magnitude data shows an acceptable functionality of the macular area. Currently the ERM does not impact the macular functionality. These results support the clinician's decision to follow the patient for possible progression of ERM.

Visual Field - OD

Single Field Analysis

Eye: Right

Name:

DOB:

ID:

Central 30-2 Threshold Test

Fixation Monitor: Gaze/Blind Spot

Stimulus: III, White

Pupil Diameter:

Date:

Fixation Target: Central

Background: 31.5 ASB

Visual Acuity:

Time:

Fixation Losses: 0/11

Strategy: SITA-Fast

RX: +3.50 DS DC X

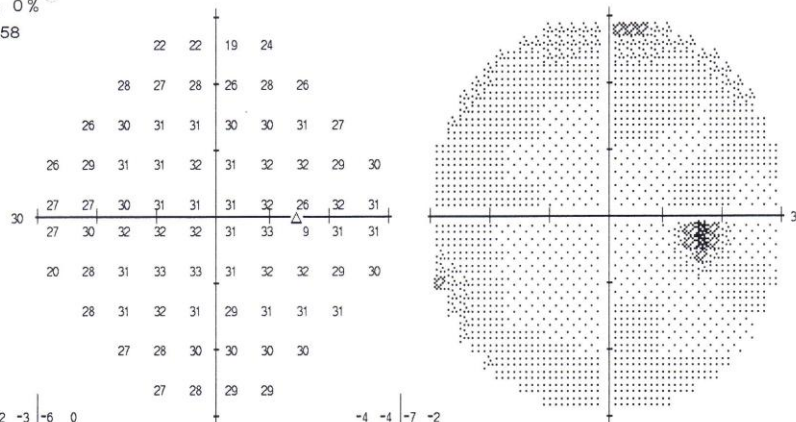
Age:

False POS Errors: 0 %

False NEG Errors: 0 %

Test Duration: 03:58

Fovea: OFF

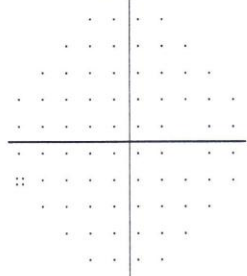


-2	-3	-6	0
1	0	1	-1
-1	1	1	2
0	0	1	0
0	-2	-1	-1
0	0	0	-1
-7	-2	0	1
0	1	1	0
-2	-1	0	0
0	0	1	0

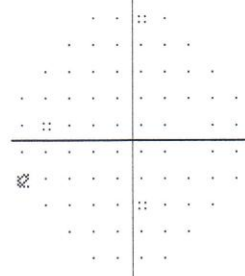
-4	-4	-7	-2
0	-2	0	-2
-2	0	0	0
-2	-1	0	-1
-1	-4	-3	-2
-2	-2	-1	-2
-8	-3	-2	0
-2	0	0	-2
-3	-3	-1	-1
-2	-1	-1	-1

GHT
Within normal limits
VFI 100%
MD +0.09 dB
PSD 1.45 dB


Total Deviation



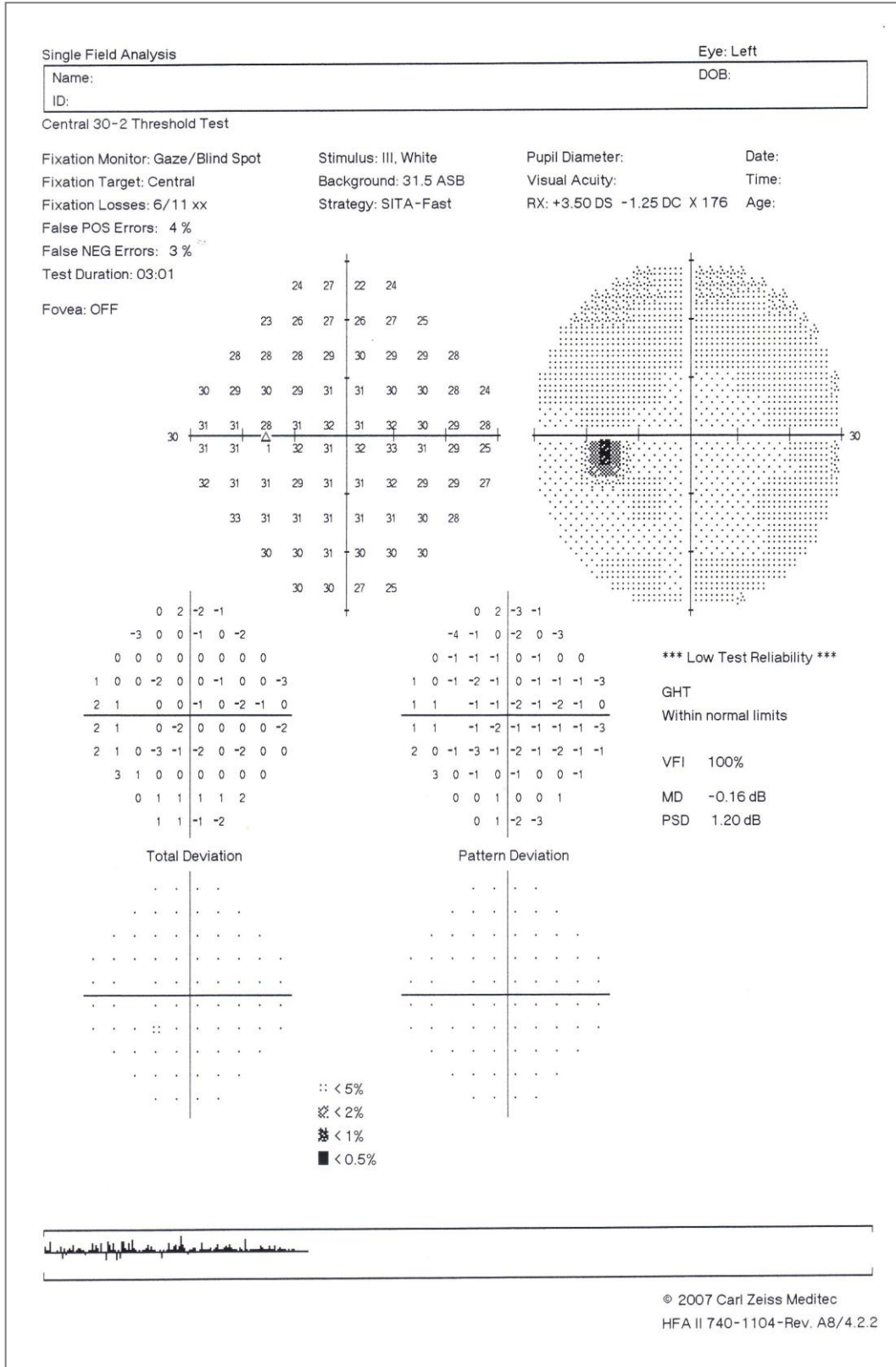
Pattern Deviation



∴ < 5%
⊗ < 2%
⊠ < 1%
■ < 0.5%



Visual Field - OS



OCT - OD

Name:

ID:

DOB:

Gender:

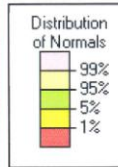



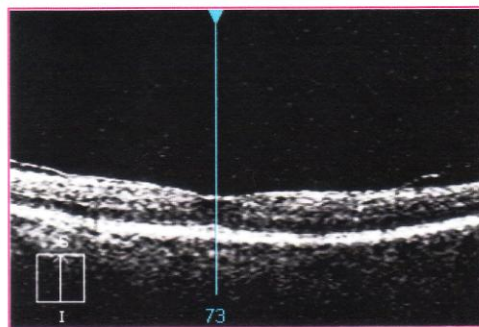
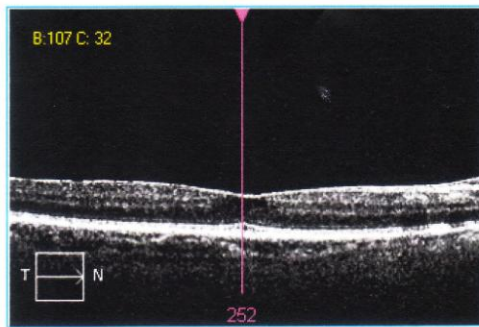
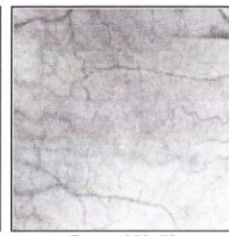
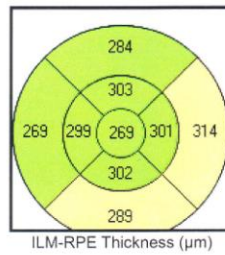
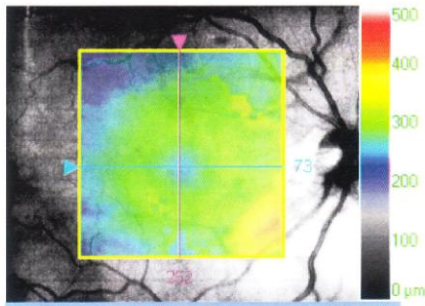
Doctor:

Signal Strength: 8/10



Macula Thickness : Macular Cube 512x128

OD OS



	Central Subfield Thickness (μm)	Cube Volume (mm^3)	Cube Average Thickness (μm)
ILM - RPE	269	10.3	287

Comments

Doctor's Signature

SW Ver: 5.1.1.6
 Copyright 2010
 Carl Zeiss Meditec, Inc
 All Rights Reserved
 Page 1 of 1

OCT - OS

Name:

ID:

DOB:

Gender:

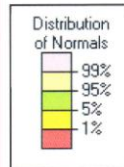



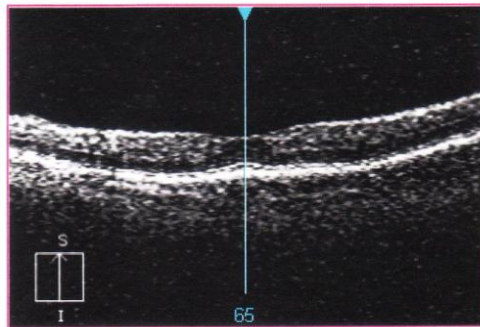
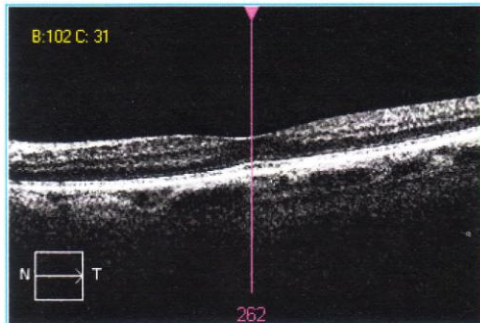
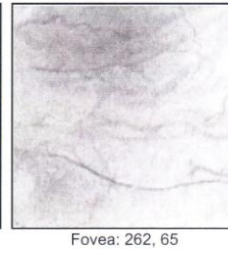
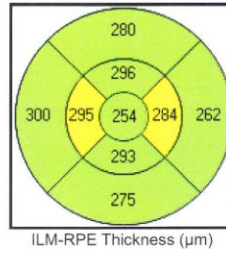
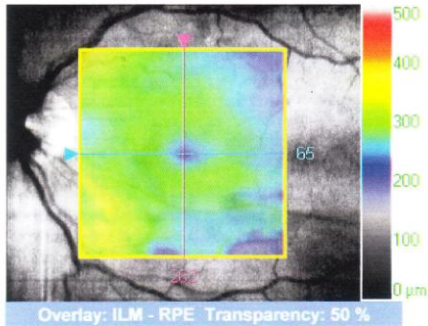
Doctor:

Signal Strength: 7/10



Macula Thickness : Macular Cube 512x128

OD OS



	Central Subfield Thickness (μm)	Cube Volume (mm^3)	Cube Average Thickness (μm)
ILM - RPE	254	10.1	281

Comments

Doctor's Signature

ERG – Concentric Stimulus Fields

DIOPSYS NOVA-ERG



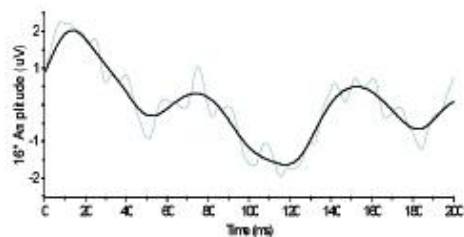
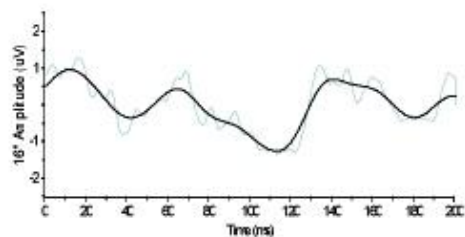


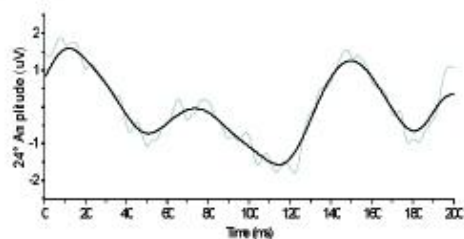
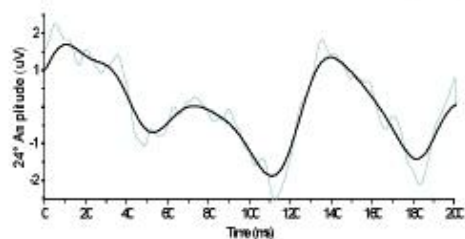
OFFICE BASED PATTERN ELECTRORETINOGRAPHY TESTING
CONCENTRIC STIMULUS FIELDS

First Name: _____ DOB: _____
 Last Name: _____ Age: _____
 Gender: _____
 Exam Date: _____ OD: _____ VA: _____
 Exam Time: _____ OS: _____ VA: _____

OD

Signal Quality: ●
94dBV 60-Hz noise

OS



Parameter	OD 24°	OD 16°	OS 24°	OS 16°
Magnitude (uV)	1.62	1.14	1.50	1.27
MagnitudeD	1.20	0.67	1.04	0.97
SNR @ 15Hz	6.3	2.2	7.6	2.2
Artifacts	1	0	0	0

Operator: _____

Comments: - Grating Size: 64

Signature: _____