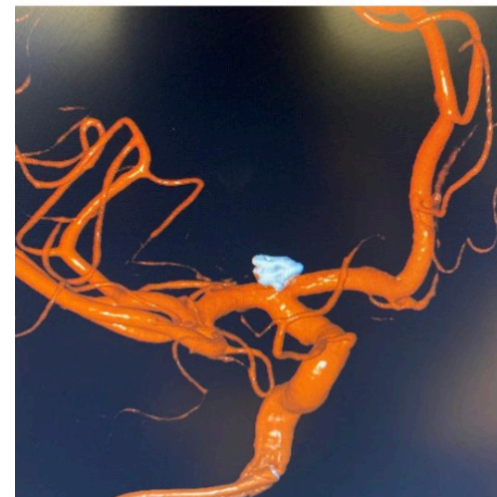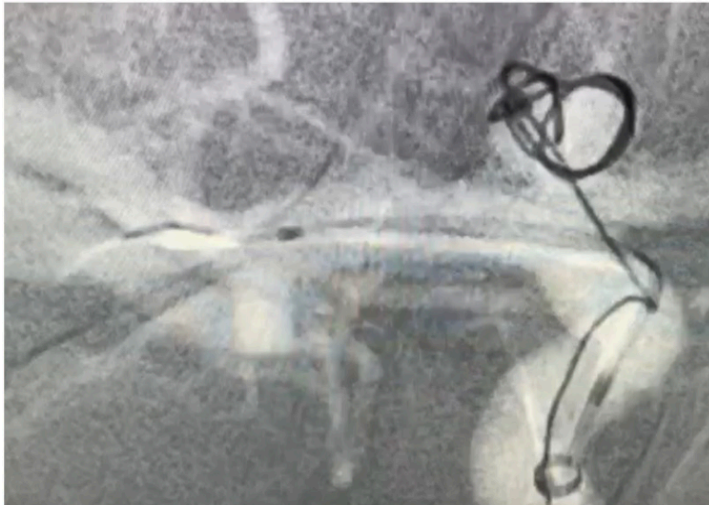
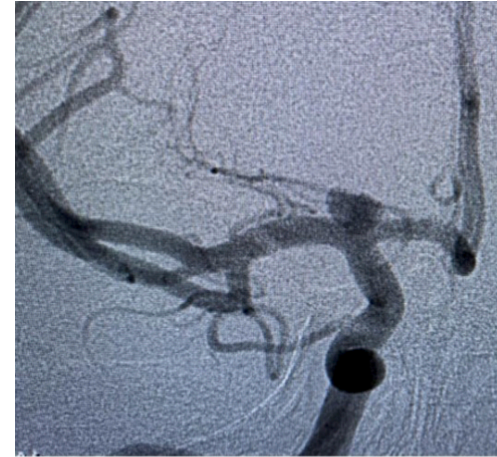
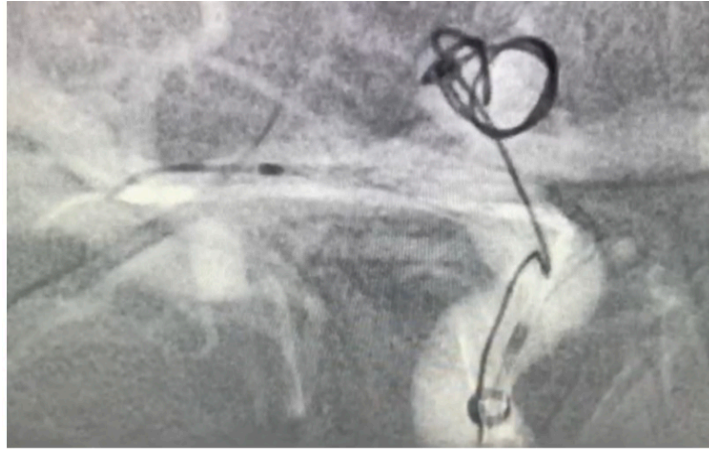


ICA Aneurysm

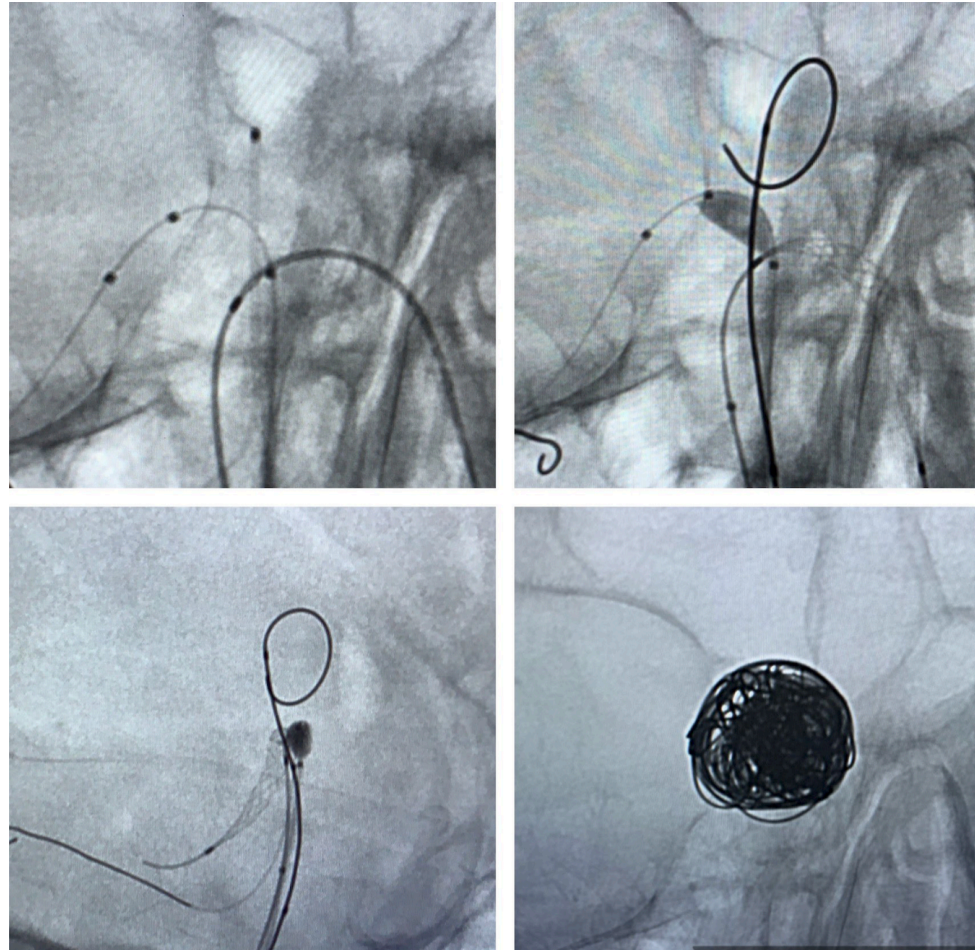
Peter Kan, MD
Baylor St. Lukes
Houston, Texas



Basilar Tip Aneurysm

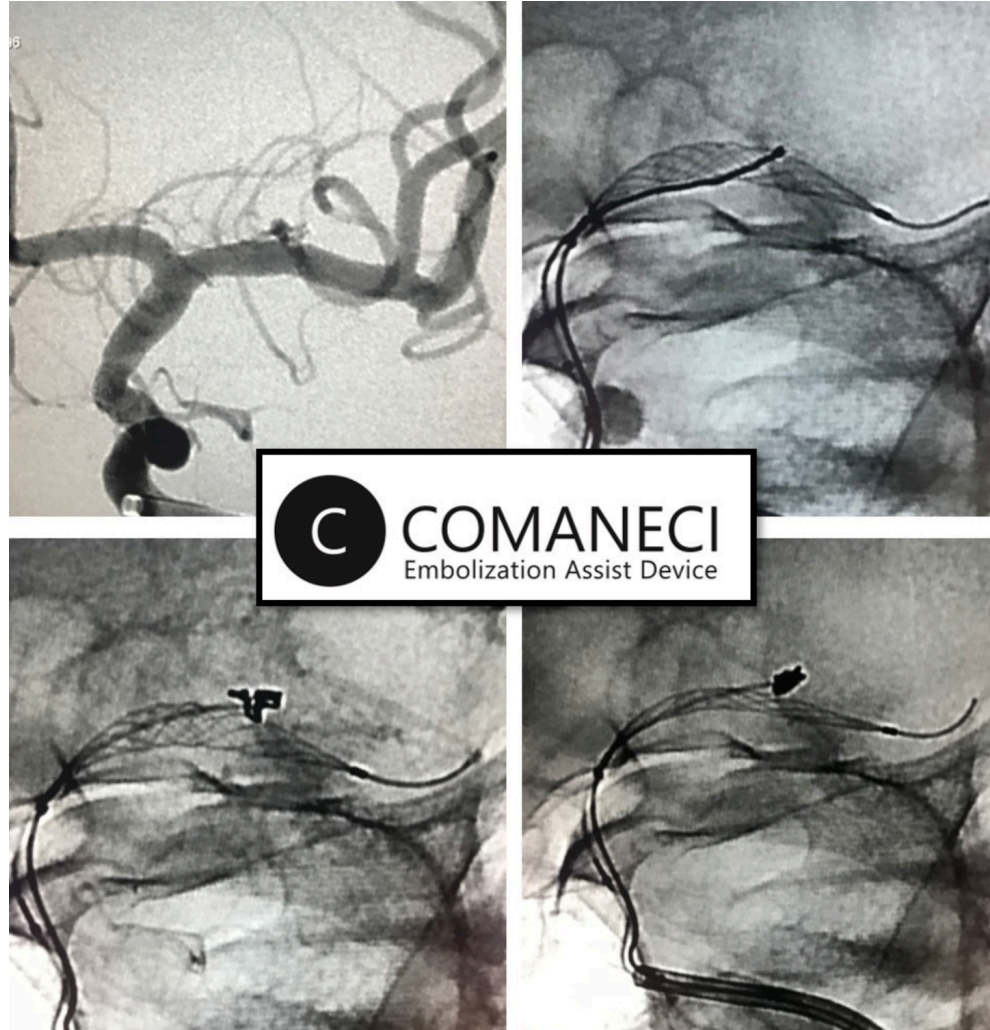
Vladimir Kalousek, MD
Zagreb, Croatia

Transaneurysmal
approach Scepter xc/
Comaneci into P1s,
followed by shunt.



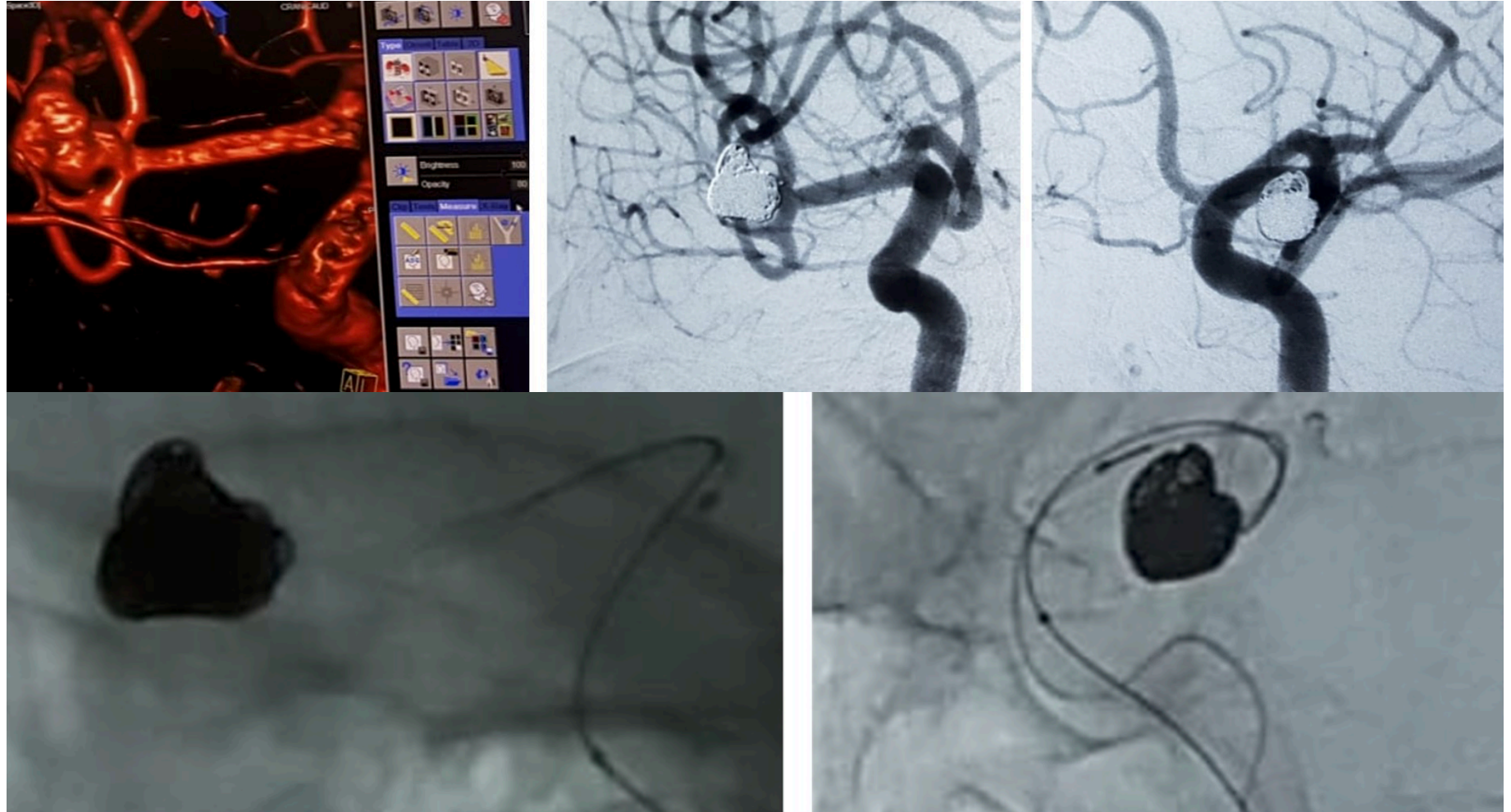
Lenticulostriate Aneurysm

Keith Woodward, MD
Fort Sanders Medical
Center
Knoxville, Tennessee



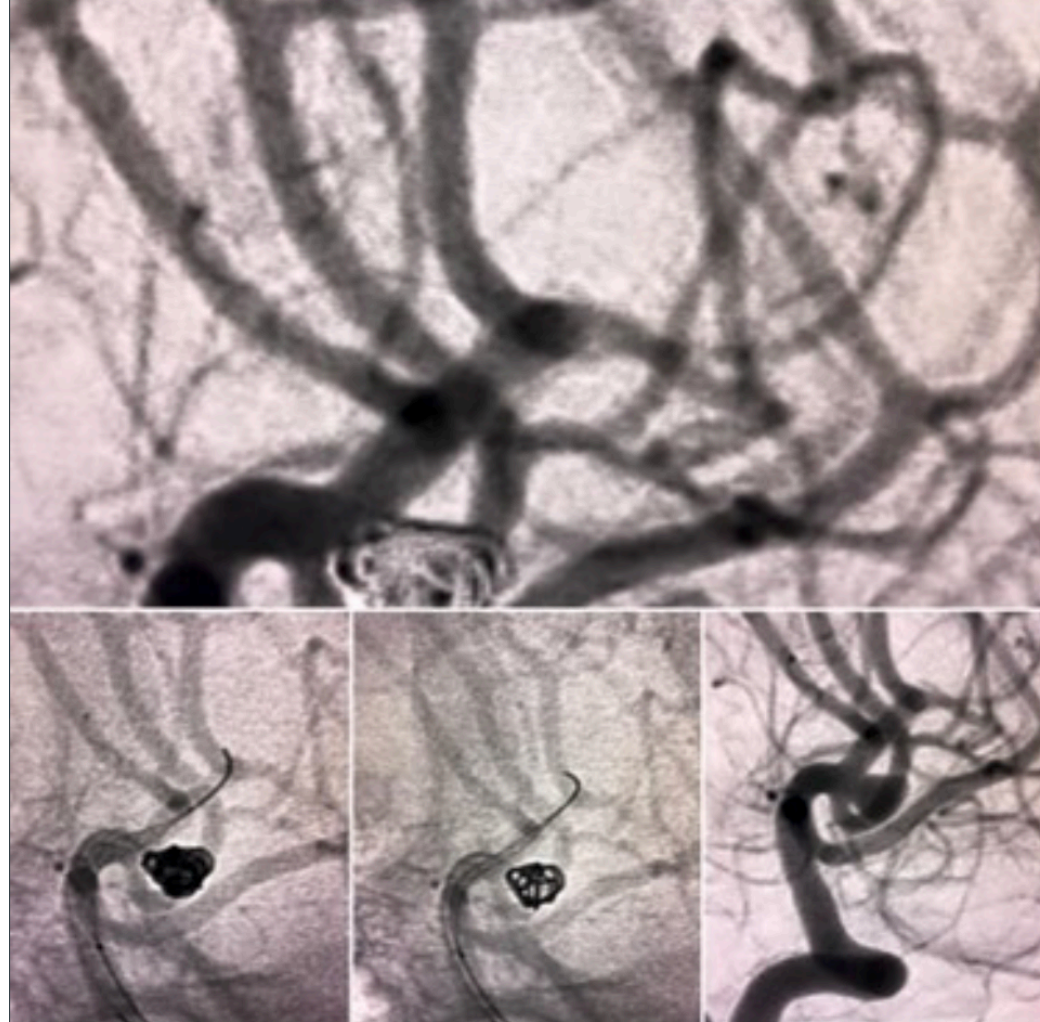
M1/M2 Aneurysm

**Yerkin Medetov,
MD
National Center
for Neurosurgery,
Nur-Sultan,
Kazakhstan**



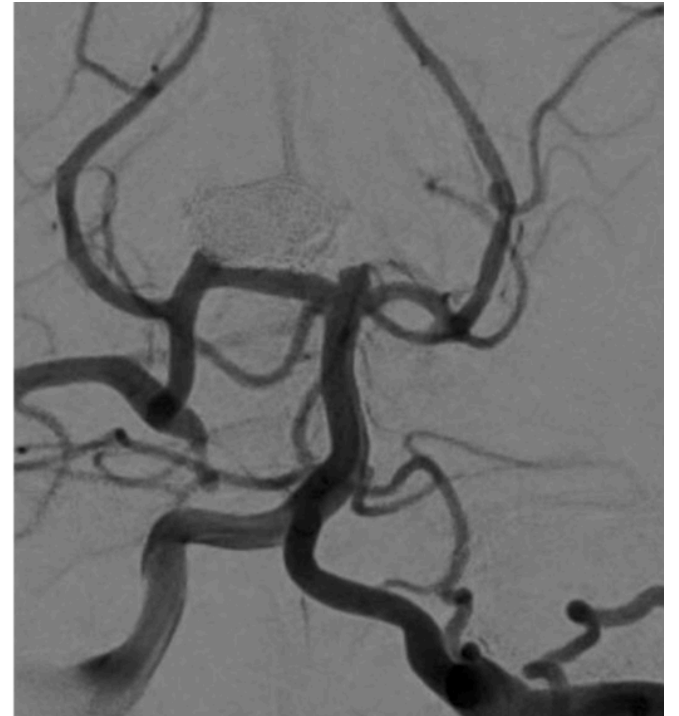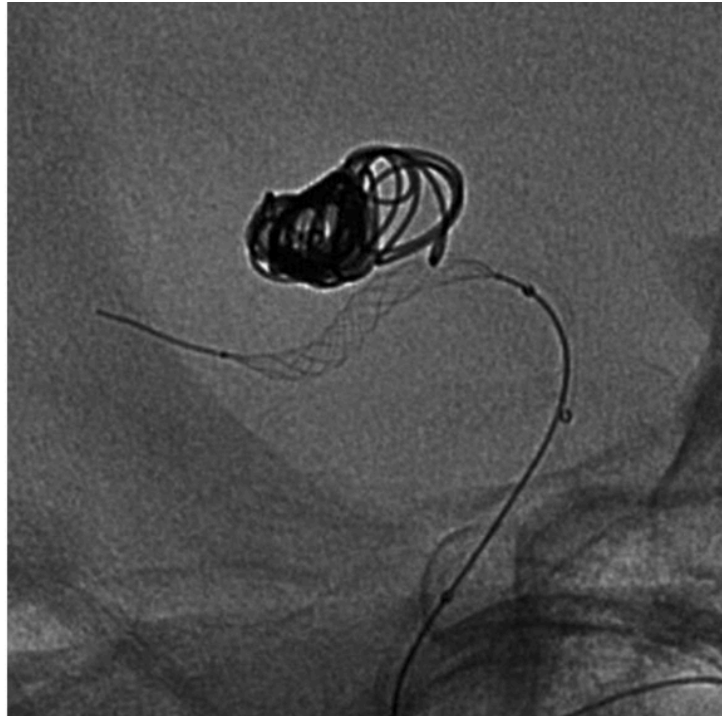
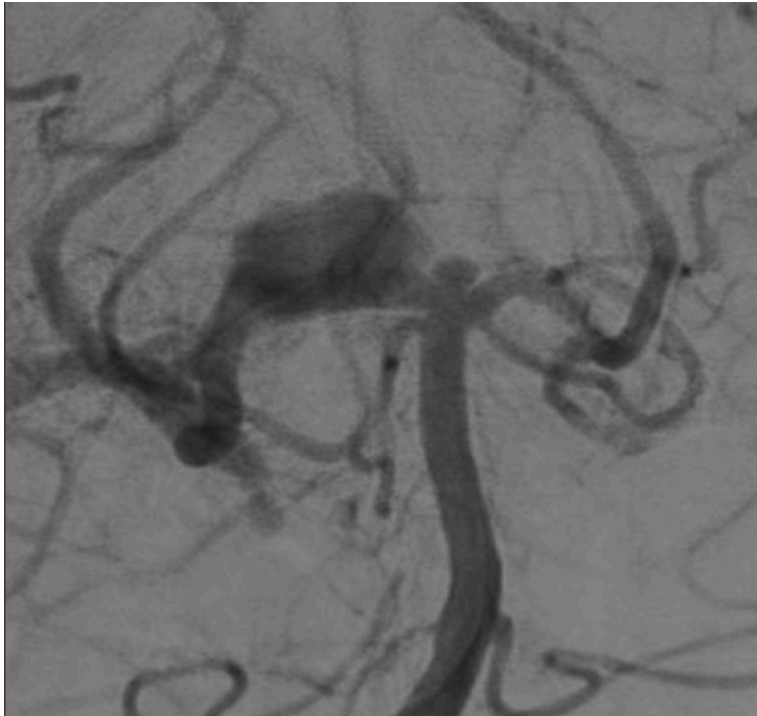
MCA Wide-necked Bifurcated Aneurysm

M. Asif Taqi, MD
Los Robles
Regional Medical
Center
Thousand Oaks,
California



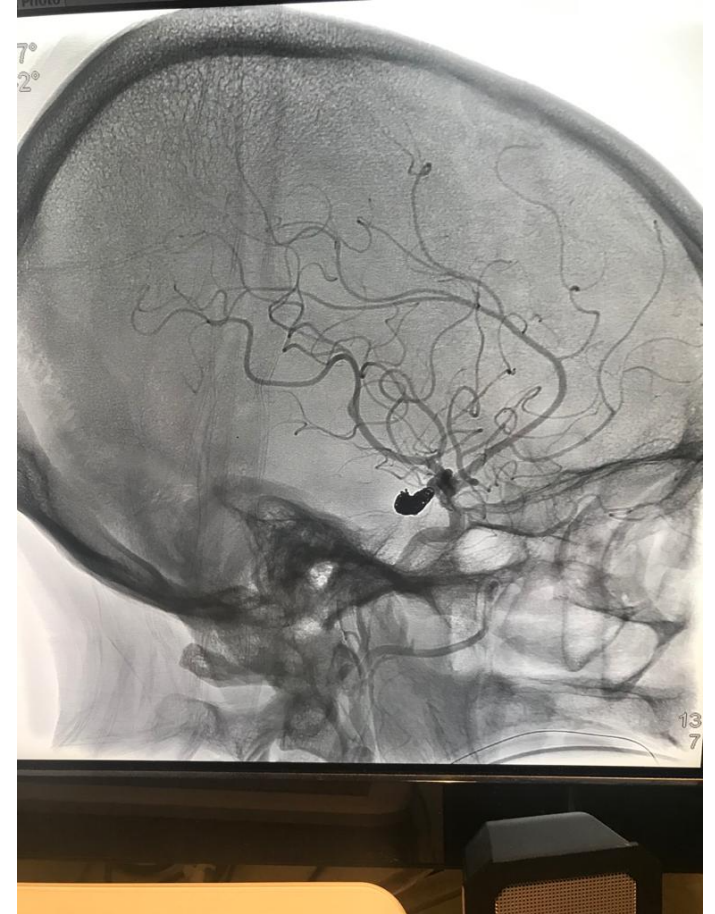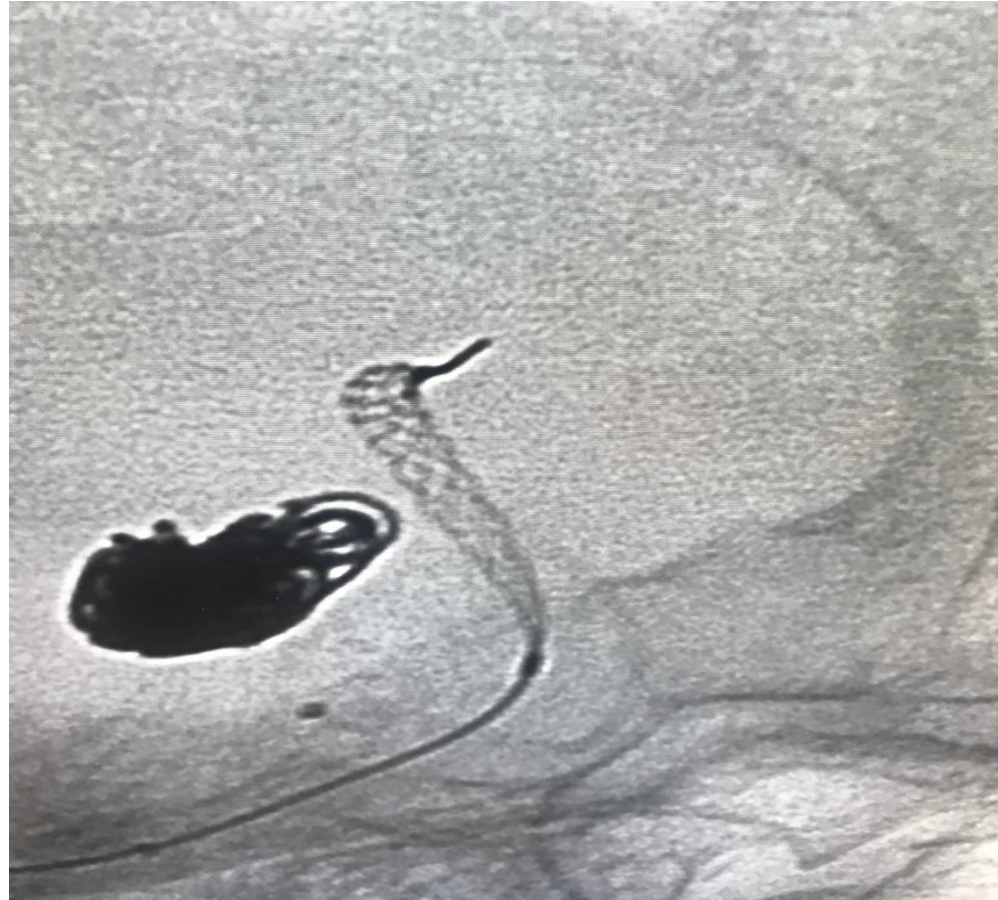PCA Aneurysm

Steve Cordina, MD
USA Health University
Hospital
Mobile, Alabama



PCA Aneurysm

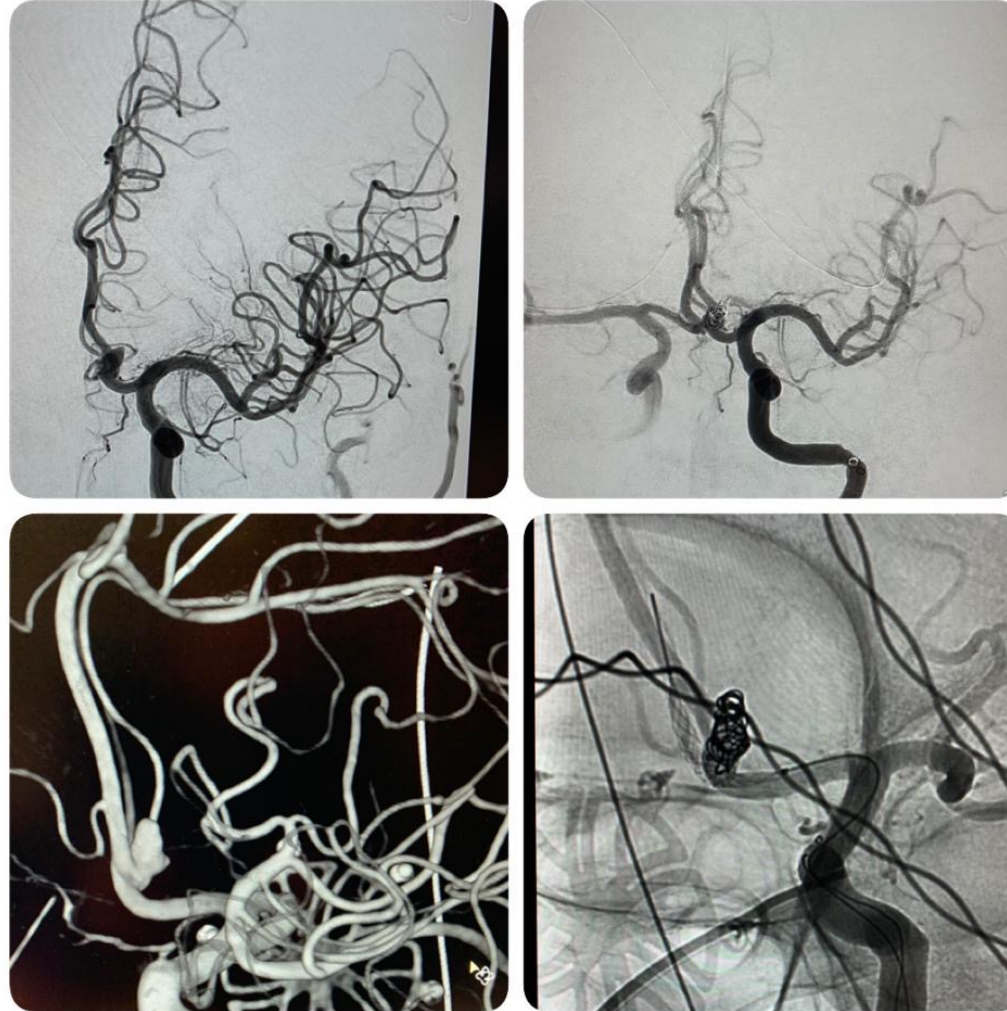
Steve Cordina, MD
USA Health University
Hospital
Mobile, Alabama



ACom Aneurysm

M. Reid Gooch, MD
Thomas Jefferson
Hospital for
Neurosciences
Philadelphia,
Pennsylvania

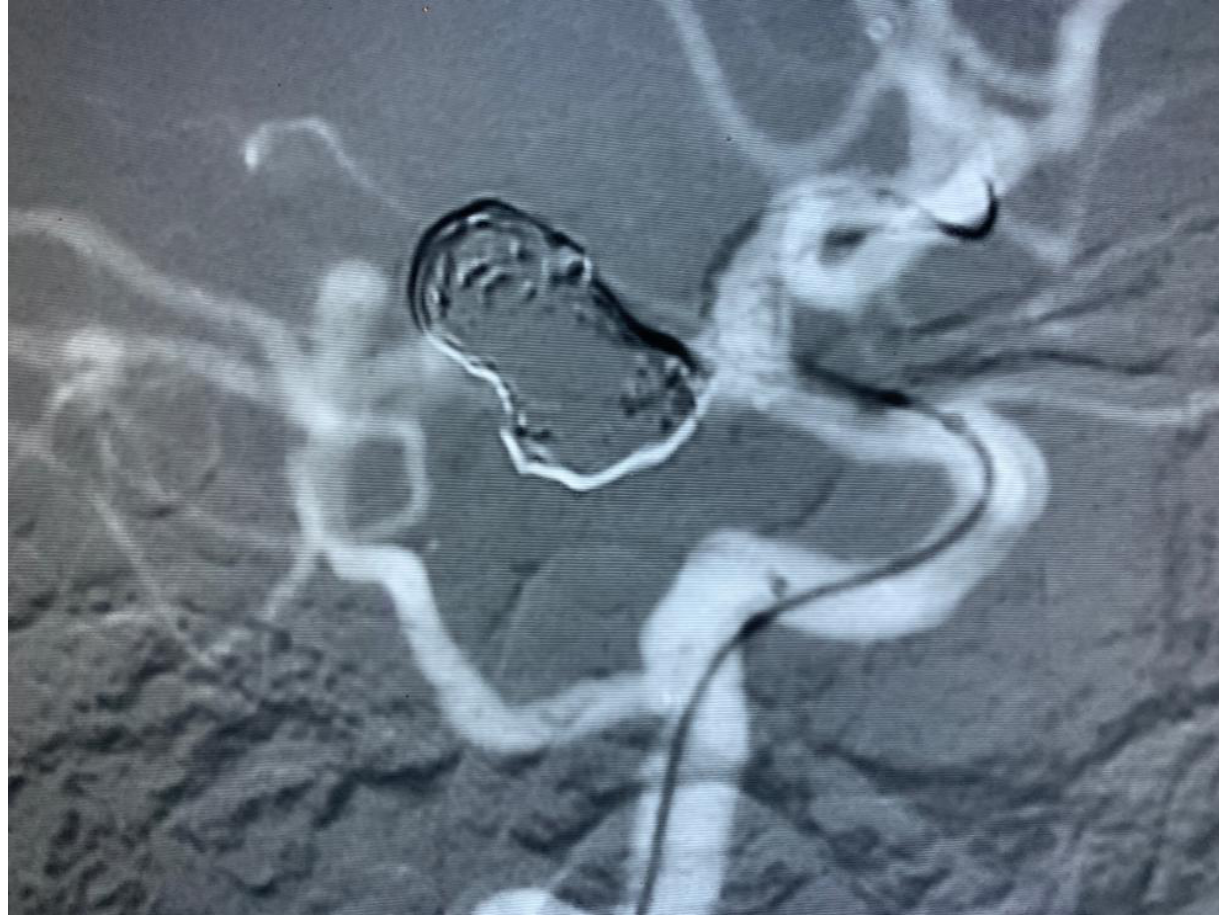Unruptured 4x5 Acom
aneurysm – Comaneci
17



PCom Aneurysm

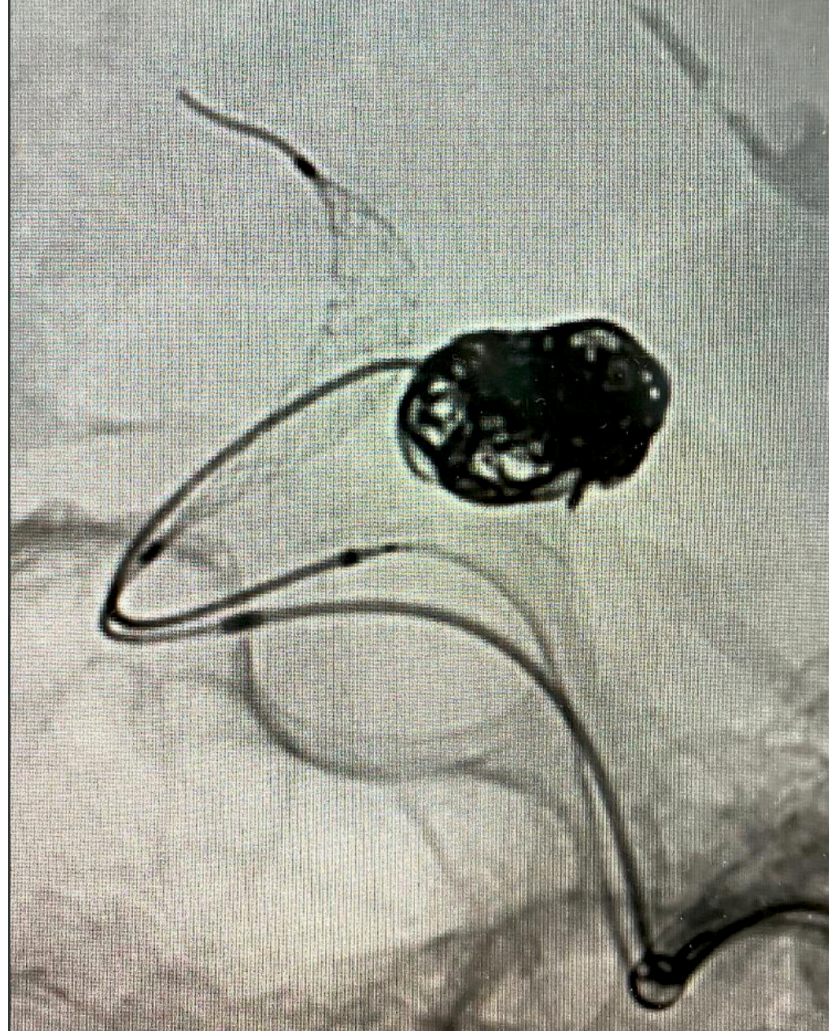**Dr. Wazni- Dr.
Raychev proctored
St. Jude Medical
Center
Fullerton, California**

PCom with Comaneci
Petit



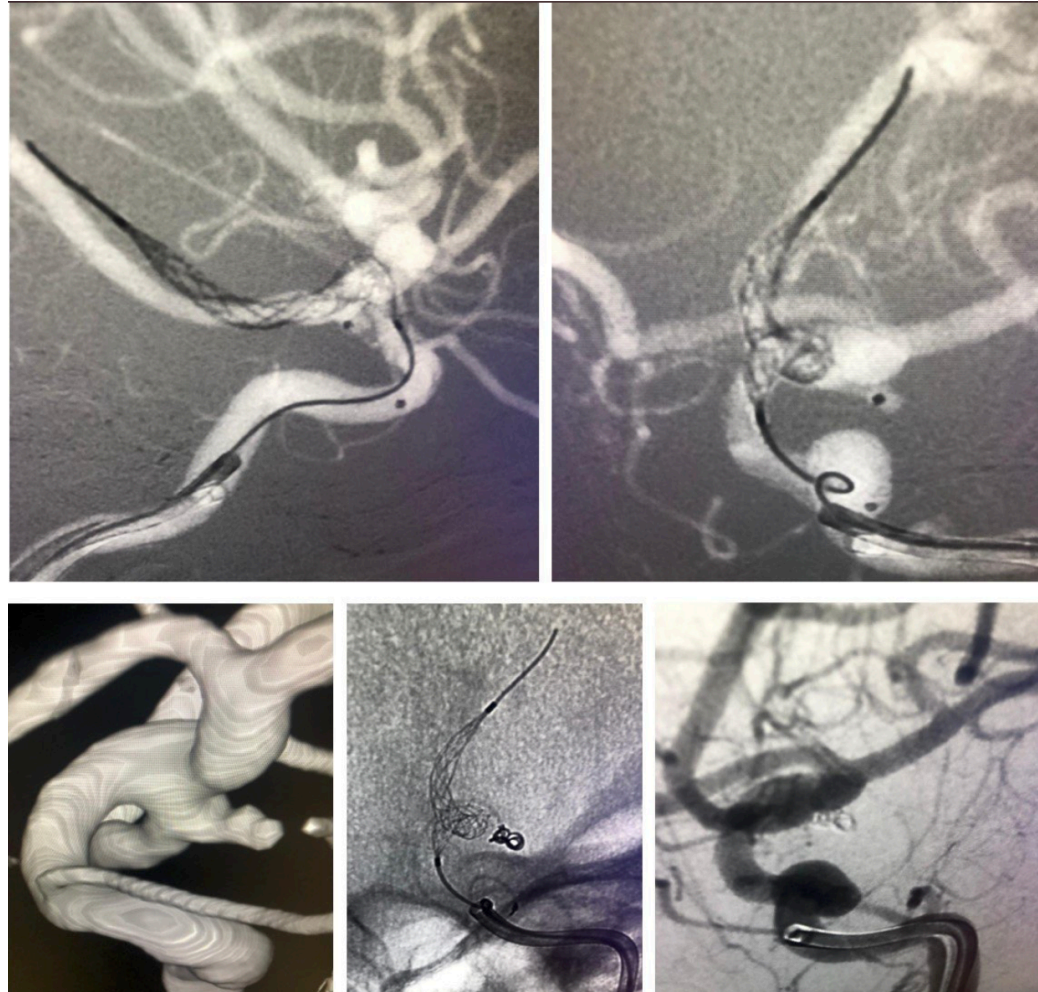Ruptured PCom Aneurysm

**Dr. Akin Oni-Orisan and
Dr. Robert Taylor
Santa Barbara Cottage
Hospital
Santa Barbara, California**



Ruptured PCom Aneurysm

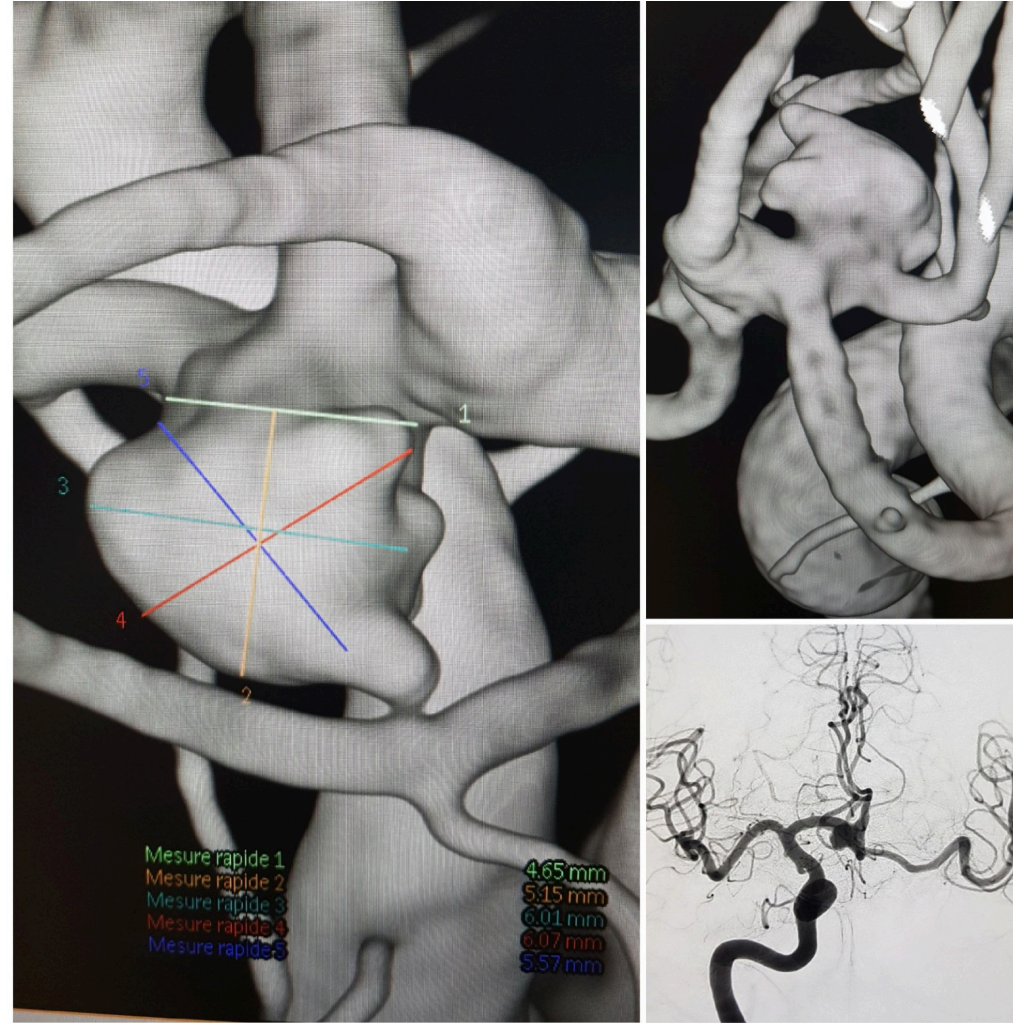
**Radoslav Raychev,
MD
St. Jude Medical
Center Fullerton,
California**



ACom Aneurysm

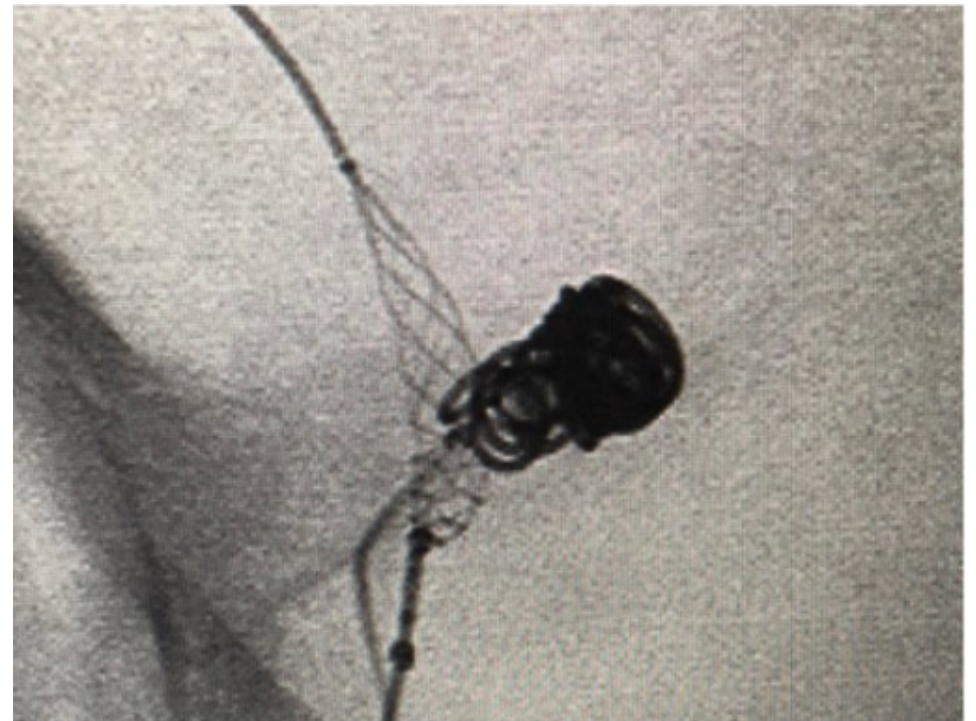
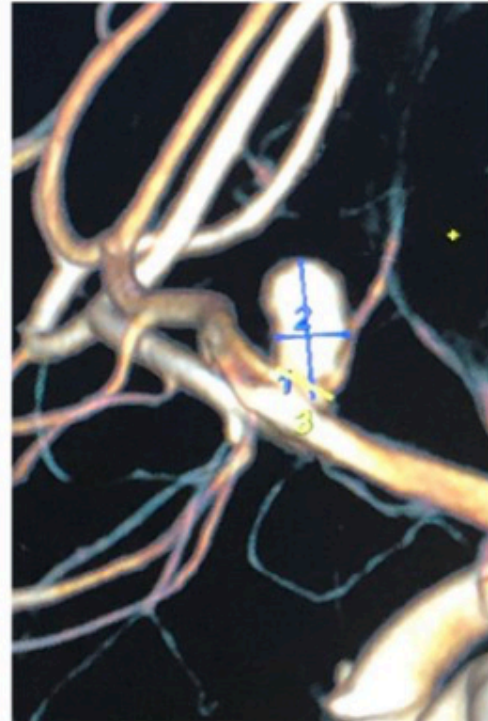
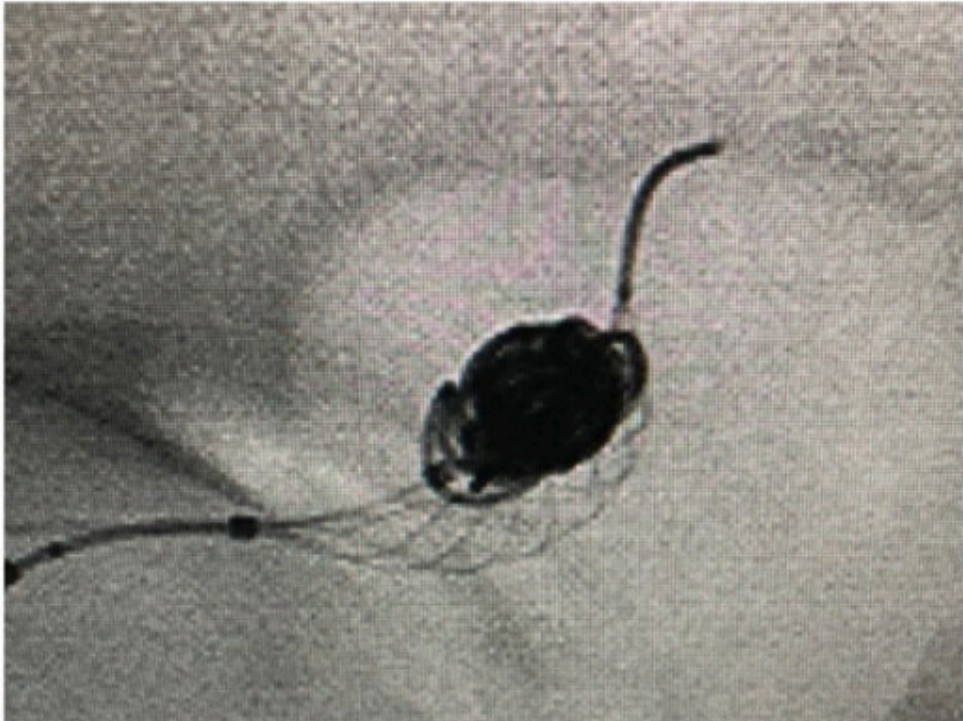
Raol Pop, MD
Strassbourg, France

Acom aneurysm 7mm
with contralateral
chronic carotid
occlusion.



Ruptured ACom Aneurysm

Ameer Hassan, MD
Harlingen, Texas



Ruptured ACom Aneurysm

Dr. Puri and Dr. Massari
University of
Massachusetts-Harvard
Medical School
Boston, Massachusetts

