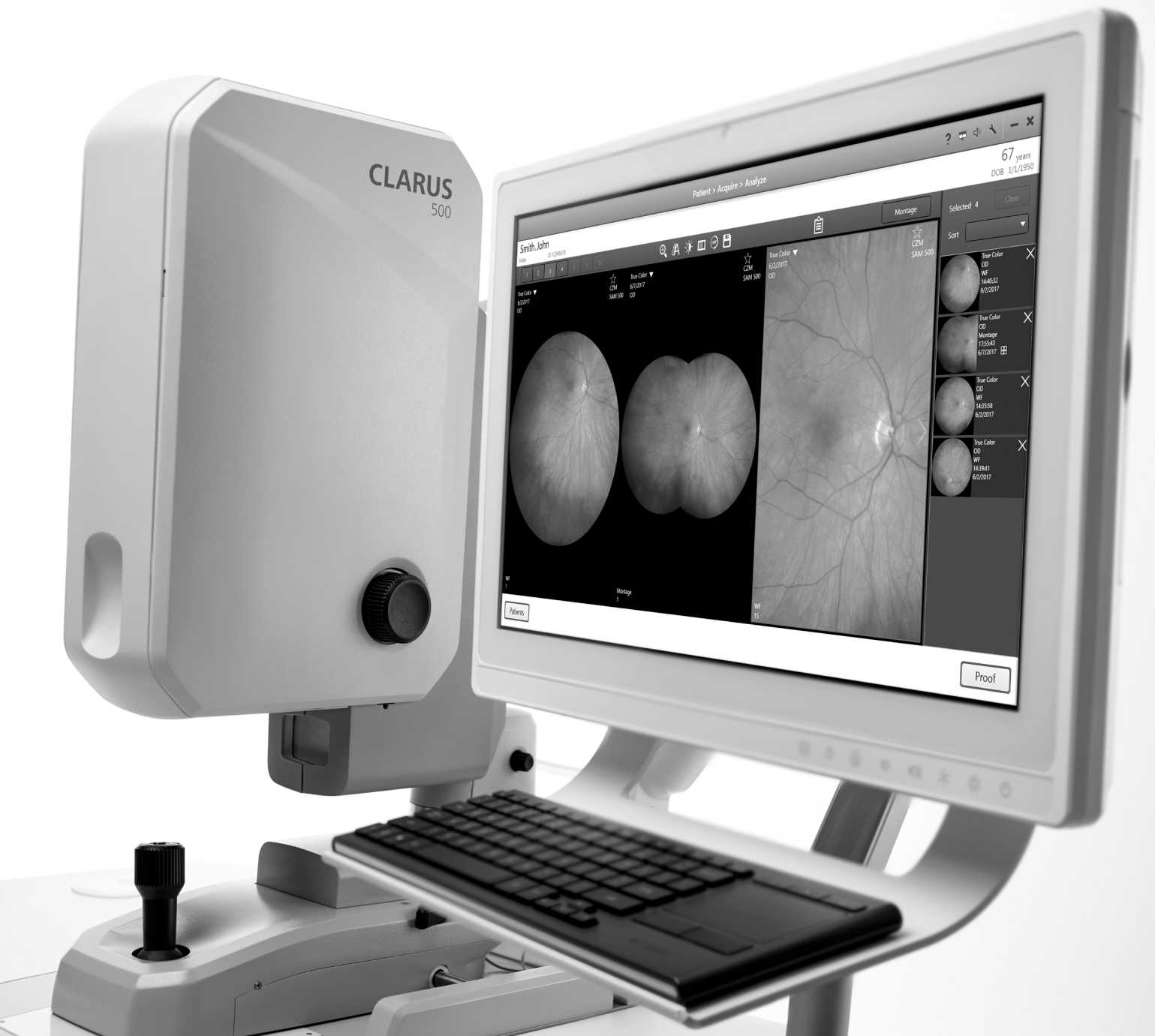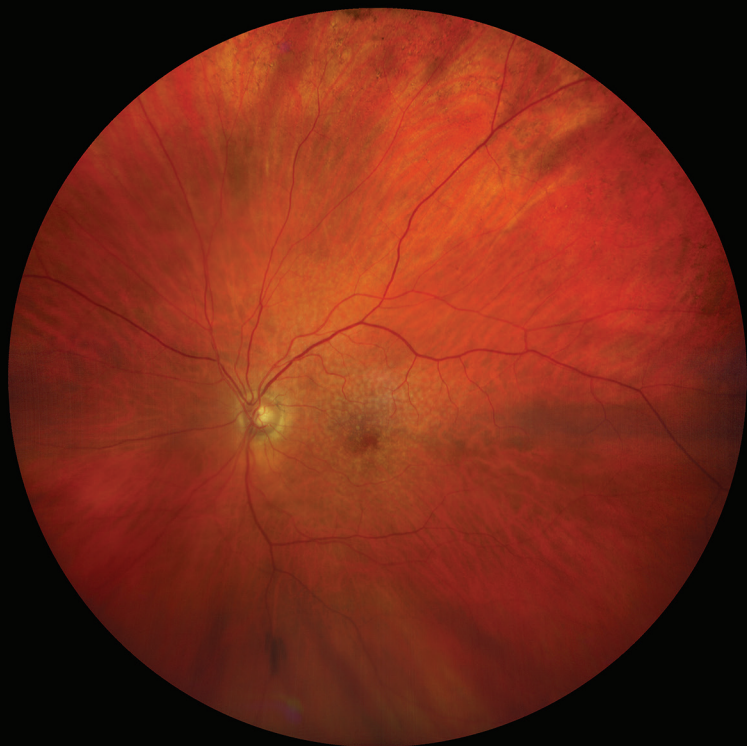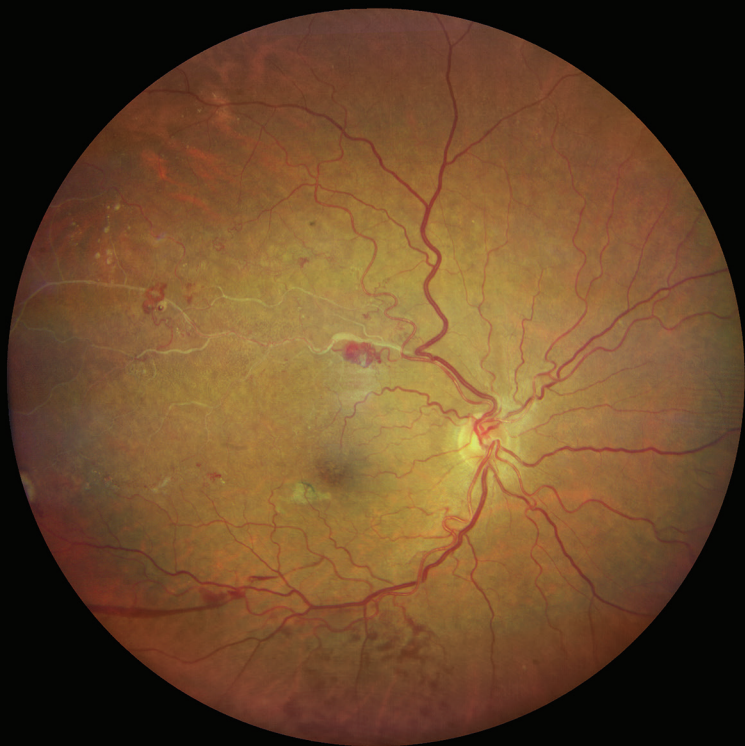
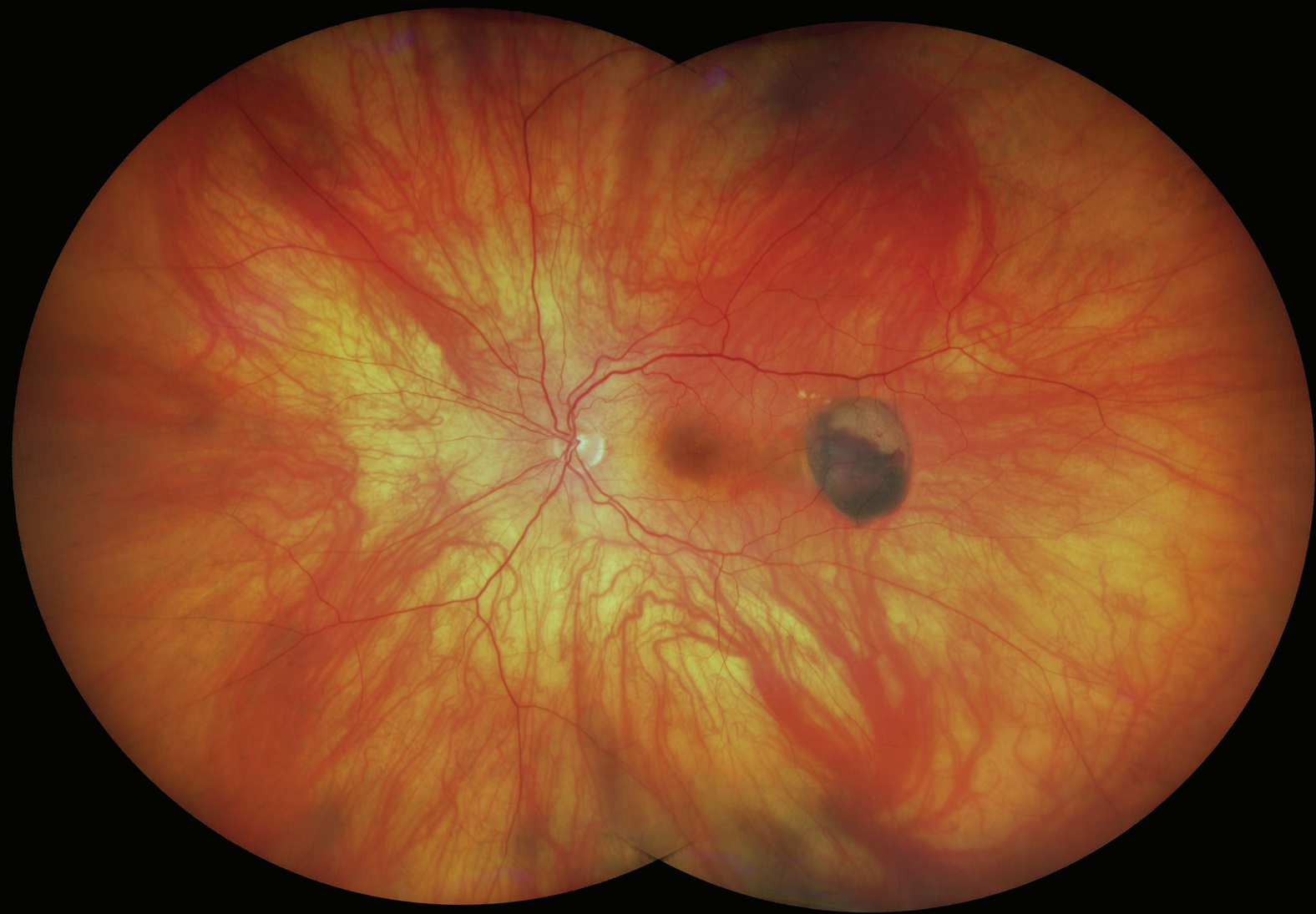




## **CLARUS 500 from ZEISS**

Analysis and Interpretation Guide





## **CLARUS 500 from ZEISS**

### HD Ultra-widefield Fundus Imaging

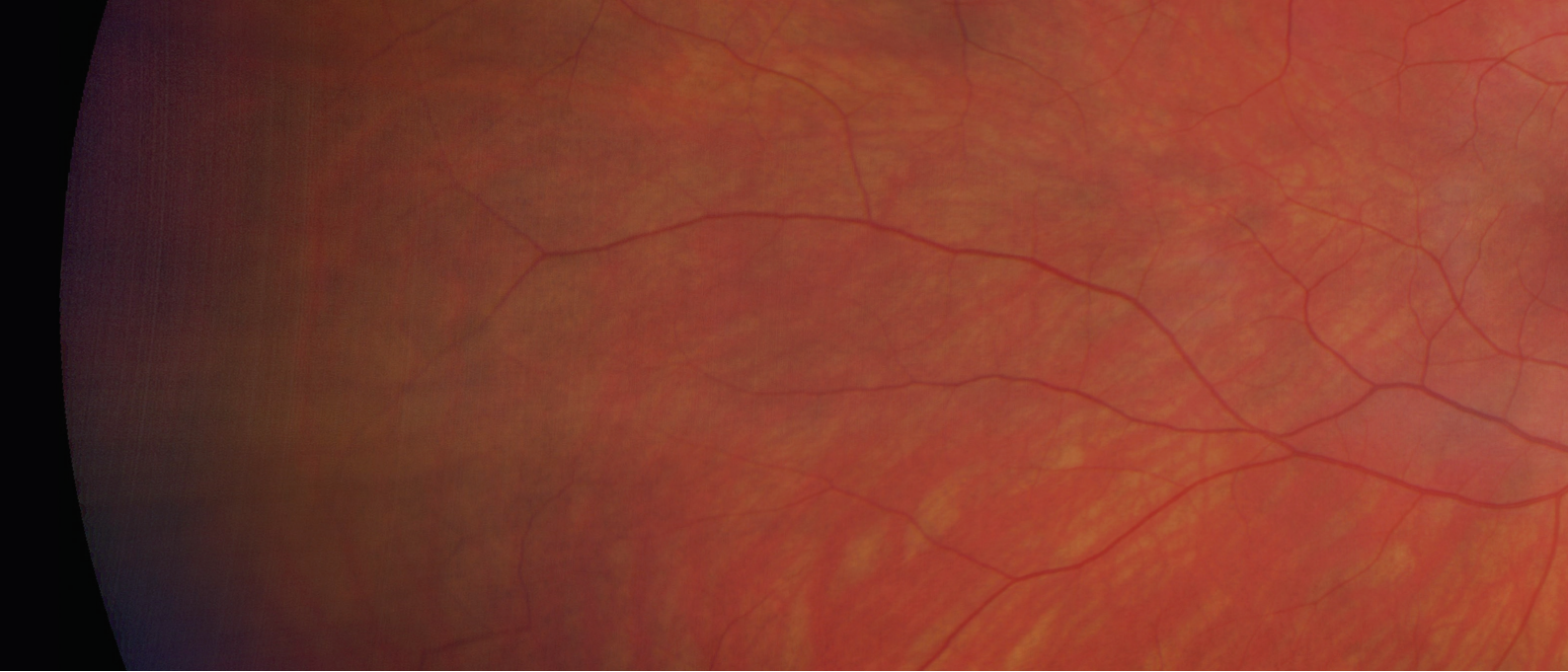
CLARUS™ 500 from ZEISS allows clinicians to easily review and compare high-quality images captured during a single session, as well as manage disease over time by providing annotation and measurement tools that allow in-depth analysis of eye health. Analysis results can be reviewed on the instrument or your computer using the review software.

With a single capture, ZEISS CLARUS 500 produces a 133° image with 7 µm resolution. HD ultra-widefield images are automatically merged to achieve 200° field of view\*.

#### **This guide explains**

- Analysis
- Overview of imaging modalities

\*Field of view is measured from the center of the eye.  
This guide is intended to help provide basic information; it is not intended to replace the User Manual.



## Analysis

You can use the analyze screens to view, compare and annotate images. Use the **Proof Sheet** (Figure 1) to browse through all available images for a single patient and to select images for review. You can filter images by exam date, laterality, scan type and/or favorite status.

On the **Review Screen** (Figure 2), you can view up to 16 images at once. You can also create montage images from up to six selected images. Annotations can be added to any image or montage, and can be copied, edited or deleted as needed. Manual measurements can be drawn anywhere on the image or montage to measure length and area.

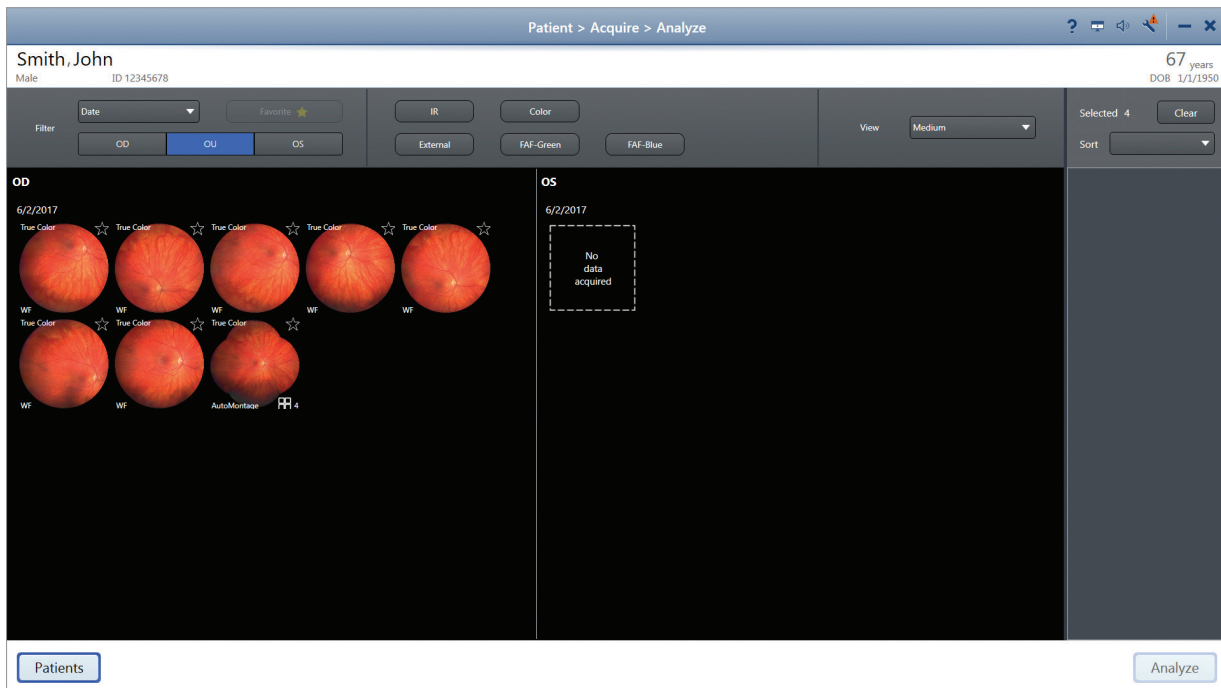
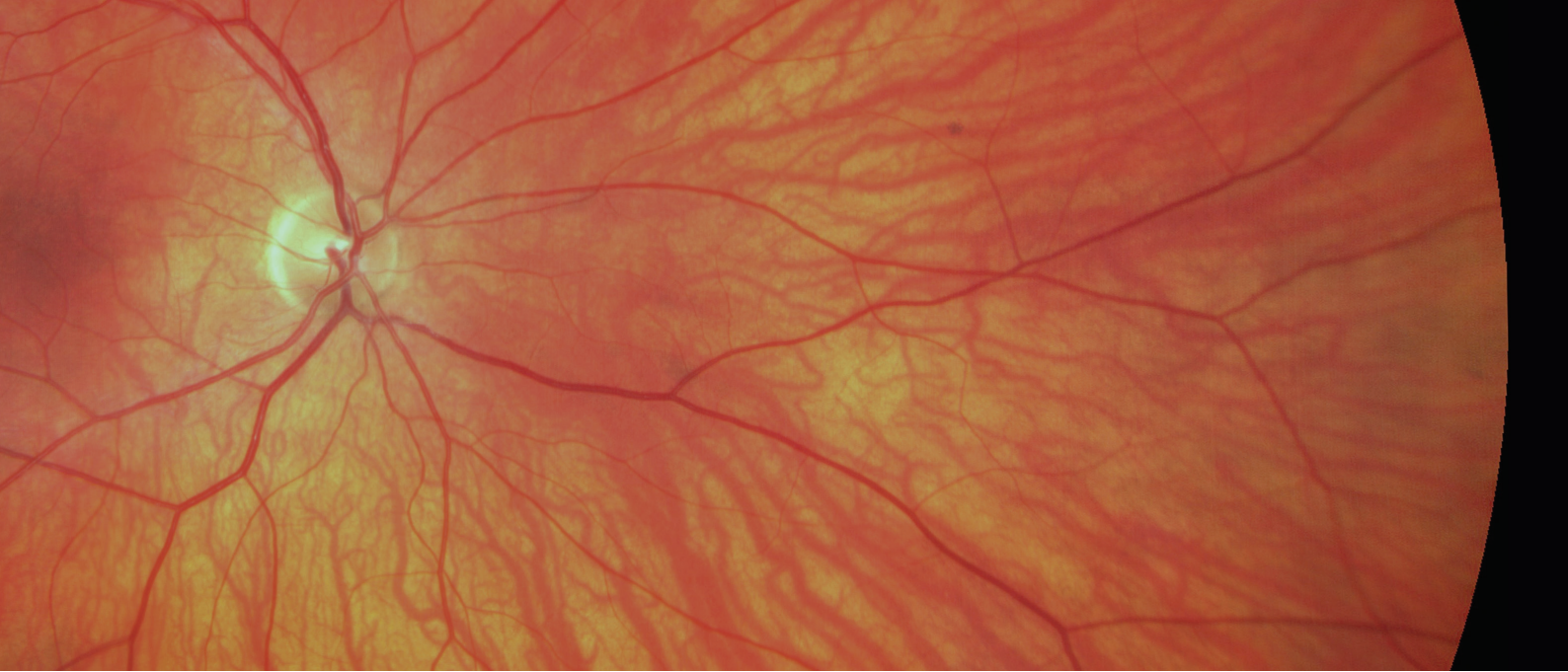

Figure 1



### Review Screen functionality

1	Number of view ports	5	Proof sheet
2	Editing toolbar	6	Patient management screen
3	Sort function	7	View ports
4	Selection bin	8	Advance arrows

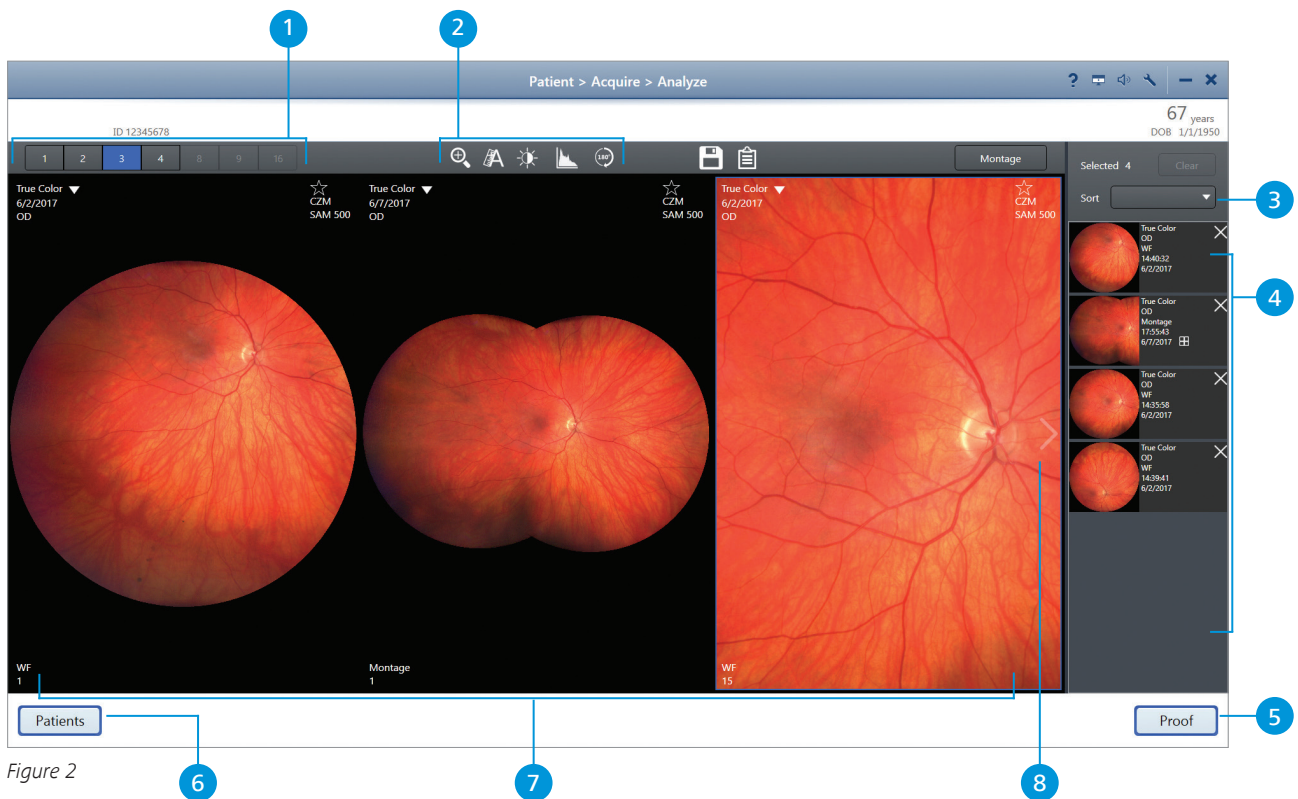


Figure 2

# Overview of imaging modalities

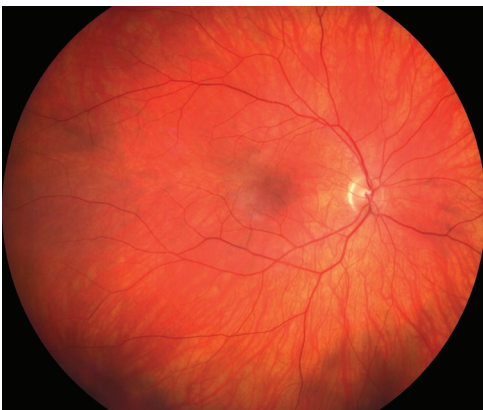
ZEISS CLARUS 500 has a range of modalities to guide your clinical assessments. This section will introduce you to the different types of images.

## True Color

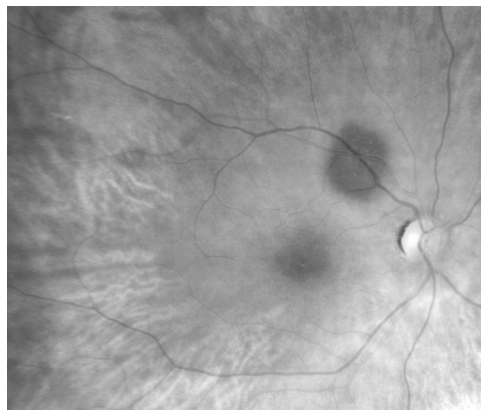ZEISS CLARUS 500 produces images that closely resemble the coloration of the fundus as seen during clinical examination. Color accuracy aids in the diagnosis and documentation of ocular disease and ensures confidence when evaluating the optic disc, nevi and lesions in which subtle color differences may lead to a change in diagnosis and management.

## RGB Channel Separation

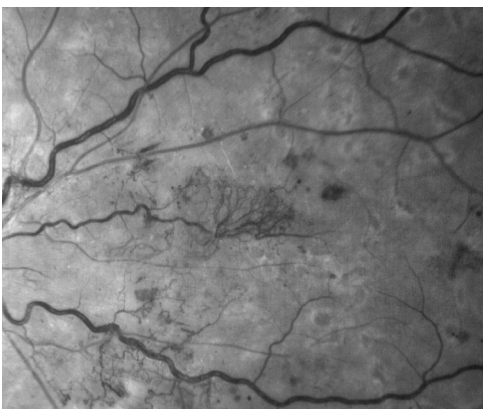
True Color images can be separated into red, green and blue channel images, which can enhance the visual contrast of details in certain layers of the retina. Red channel images reveal the choroid in more detail. This may be helpful in visualizing choroidal lesions such as nevi or tumors. Green channel images provide excellent contrast of the retina, especially of vasculature and hemorrhages. Blue channel images increase visibility of the anterior retinal layers, allowing easier visualization of retinal nerve fiber layer (RNFL) defects and epiretinal membranes.



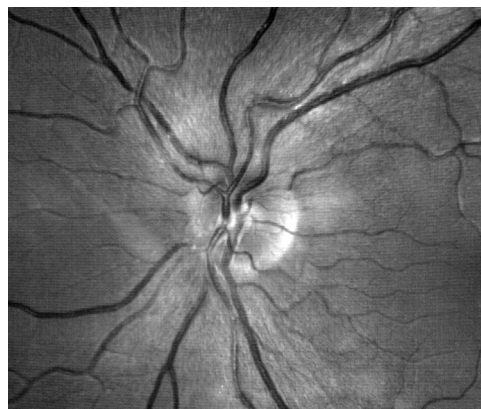
*True Color image of a healthy eye*



*Red channel image of a choroidal nevus*



*Green channel image of diabetic retinopathy*



*Blue channel image of the RNFL of a healthy eye*

### **Fundus Autofluorescence (FAF)**

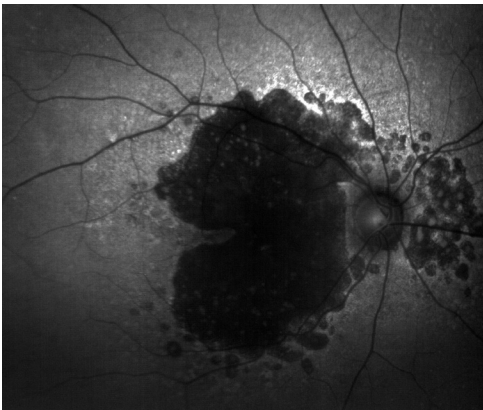
Fundus autofluorescence images allow clinicians to visualize lipofuscin fluorescence in the retinal pigment epithelium (RPE), an indicator of RPE health. Healthy RPE appears as a uniform gray color on FAF images. In general, hyper-autofluorescence (bright) indicates RPE damage, and hypo-autofluorescence (dark) indicates dead or absent RPE. FAF-Blue images have been shown to reveal early RPE disruption in macular degeneration and predict progression of geographic atrophy. FAF-Green images may be less affected by media opacities such as nuclear sclerotic cataracts.

### **Infrared (IR)**

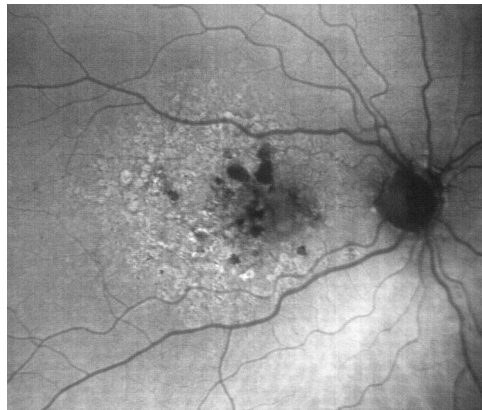
Infrared light is used to capture these images with the unique property of increased penetration through tissue, providing improved visualization of choroidal structures. Deeply pigmented structures absorb infrared wavelengths, resulting in a darker appearance.

### **External**

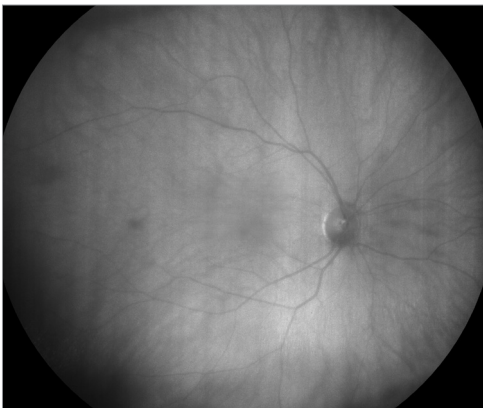
High-resolution external eye images allow for documentation of ocular surface and adnexa conditions such as corneal ulcers.



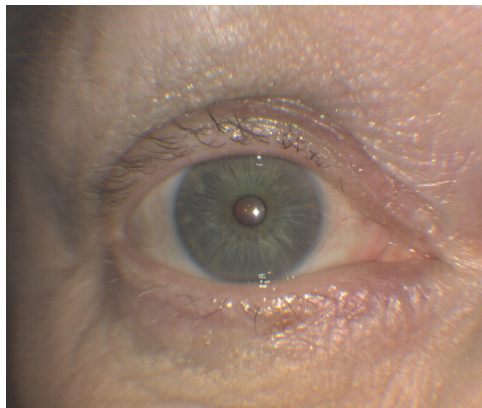
*Fundus autofluorescence-Blue (FAF-Blue) image of geographic atrophy*



*Fundus autofluorescence-Green (FAF-Green) image of dry age-related macular degeneration*



*Infrared (IR) reflectance image of a healthy eye*



*External eye image*

Images and diagnoses courtesy of Roger Goldberg, MD, Jesse Jung, MD, and Michael H. Chen, OD\*\*.

\*\*The diagnoses provided by the healthcare professionals reflect only their personal opinions and experiences and do not necessarily reflect the opinions of any institution with whom they are affiliated. The healthcare professionals credited in this interpretation guide have a contractual relationship with Carl Zeiss Meditec, Inc., and have received financial compensation.



**Carl Zeiss Meditec, Inc.**  
5160 Hacienda Drive  
Dublin, CA 94568  
USA  
[www.zeiss.com/us/clarus](http://www.zeiss.com/us/clarus)  
[www.zeiss.com/med](http://www.zeiss.com/med)



**Carl Zeiss Meditec AG**  
Goeschwitzer Strasse 51–52  
07745 Jena  
Germany  
[www.zeiss.com/clarus](http://www.zeiss.com/clarus)  
[www.zeiss.com/med/contacts](http://www.zeiss.com/med/contacts)

**US\_31\_020\_00061** Printed in the United States. CZ-VIII/2017 United States edition: Only for sale in selected countries. The contents of this reference guide may differ from the current status of approval of the product or service offering in your country. Please contact our regional representatives for more information. Subject to change in design and scope of delivery and as a result of ongoing technical development. CLARUS is either a trademark or a registered trademark of Carl Zeiss Meditec AG or other companies of the ZEISS Group in Germany and/or other countries.  
© Carl Zeiss Meditec, Inc., 2017. All rights reserved.